



Acetaminophen

Updated: January 28, 2016.

OVERVIEW

Introduction

Acetaminophen is a widely used nonprescription analgesic and antipyretic medication for mild-to-moderate pain and fever. Harmless at low doses, acetaminophen has direct hepatotoxic potential when taken as an overdose and can cause acute liver injury and death from acute liver failure. Even in therapeutic doses, acetaminophen can cause transient serum aminotransferase elevations.

Background

Acetaminophen (a seet" a min' oh fen), which is known as paracetamol in Europe, is an aminophenol that is believed to act centrally as an analgesic and antipyretic agent. While technically a nonsteroidal antiinflammatory drug (NSAID), acetaminophen unlike typical NSAIDs (ibuprofen, naproxen, indomethacin) has only minor effects on tissue cyclooxygenase activity (Cox-1 and Cox-2) and appears to produce analgesia by increasing pain thresholds, perhaps through inhibition of the nitric oxide pathway which is activated by many pain neurotransmitter receptors. Acetaminophen has lower antiinflammatory activity than aspirin or typical NSAIDs. Acetaminophen is typically recommended for management of minor aches and pains from the common cold, viral and bacterial infections, sinusitis, headache, toothache, back ache, muscle strain, tendonitis, osteoarthritis, trauma or menstrual cramps. Acetaminophen has been available as an over-the-counter preparation in the United States since 1960. In 2011, an intravenous formulation of acetaminophen was approved in the United States for adults and children above the age of 2 years. The recommended oral dose is 660 to 1000 mg every 4 to 6 hours, but should not to exceed 3 grams per day. Multiple generic formulations of acetaminophen are available (e.g., Tylenol, Anacin Aspirin Free, Feverall, Neopap, Panadol and Tempra) in capsules or tablets of 330 or 500 mg each. Liquid formulations for children are available in concentrations that vary from 15 to 100 mg/mL; the dosage in children should be carefully chosen and kept to less than 75 mg/kg/day. In addition, acetaminophen is a frequent component in many over-the-counter and prescription combinations with decongestants and/or antihistamines for cold and allergy symptoms, or as a sleeping aid and with other analgesics (such as oxycodone, hydrocodone, dilaudid and codeine) for moderate-to-severe forms of pain. Common products in the United States include: Tylenol-PM, Nyquil, Darvocet, Vicodin, and many others. Acetaminophen is one of the most commonly used medications in the United States and more than 25 billion doses are sold yearly.

Hepatotoxicity

Chronic therapy with acetaminophen in doses of 4 grams daily has been found to lead to transient elevations in serum aminotransferase levels in a proportion of subjects, generally starting after 3 to 7 days, and with peak values rising above 3-fold elevated in 39% of persons. These elevations are generally asymptomatic and resolve

rapidly with stopping therapy or reducing the dosage, and in some instances resolve even with continuation at full dose (Case 1).

While acetaminophen has few side effects when used in therapeutic doses, recent reports suggest that its standard use can result in severe hypersensitivity reactions including Stevens Johnson syndrome (SJS) and toxic epidermal necrolysis (TEN). Both of these syndromes can be life-threatening and both may be accompanied by evidence of liver injury. However, the hepatic involvement is usually mild and marked only by asymptomatic mild-to-moderate elevations in serum aminotransferase levels.

The best known form of hepatotoxicity from acetaminophen is an acute, serious hepatocellular injury as a result of intentional or unintentional overdose. The injury is due to a direct, toxic effect of the high doses of acetaminophen. Acetaminophen hepatotoxicity most commonly arises after a suicide attempt using more than 7.5 grams (generally more than 15 grams) as a single overdose (Case 2). Hepatic injury generally starts 24 to 72 hours after the ingestion with marked elevations in serum ALT and AST (often to above 2000 U/L), followed at 48 to 96 hours by clinical symptoms: jaundice, confusion, hepatic failure and in some instances death. Evidence of renal insufficiency is also common. Serum aminotransferase levels fall promptly and recovery is rapid if the injury is not too severe. Similar injury can occur with high therapeutic or supratherapeutic doses of acetaminophen given over several days for treatment of pain and not as a purposeful suicidal overdose (Case 3). This form of acetaminophen hepatotoxicity is referred to as accidental or unintentional overdose, and usually occurs in patients who have been fasting, or are critically ill with a concurrent illness, alcoholism or malnutrition, or have preexisting chronic liver disease. Some cases of unintentional overdose occur in patients taking acetaminophen in combinations with controlled substances (oxycodone, codeine), who take more than recommended amounts over several days in attempts to control pain or withdrawal symptoms. Instances of unintentional overdose in children are often due to errors in calculating the correct dosage or use of adult sized tablets instead of child or infant formulations. Because acetaminophen is present in many products, both by prescription and over-the-counter, another problem occurs when a patient ingests full or high doses of several products unaware that several contain acetaminophen.

Likelihood score: A[HD] (well established cause of liver injury, but severe cases occur only with high doses).

Mechanism of Injury

The mechanism of acetaminophen hepatotoxicity has been extensively analyzed in humans and in animal models. Acetaminophen is largely converted to nontoxic glucuronate or sulfate conjugates and secreted in the urine. A minor amount of acetaminophen is metabolized via the cytochrome P450 system to intermediates that can be toxic, particularly N-acetyl-p-benzoquinoneimine. Ordinarily, this intermediate is rapidly conjugated to reduced glutathione, detoxified and secreted. If levels of glutathione are low or the pathway is overwhelmed by high doses of acetaminophen, the reactive intermediate accumulates and binds to intracellular macromolecules that can lead to cell injury, usually through apoptotic pathways. Factors that increase the metabolism of acetaminophen through the P450 system (certain drugs, chronic alcohol use) or that decrease the availability of glutathione (fasting, malnutrition, alcoholism) can predispose to acetaminophen toxicity. Factors that affect downstream toxicity of acetaminophen metabolic intermediates may also affect toxicity. These factors are important in designing therapies for acetaminophen hepatotoxicity.

Outcome and Management

The minor aminotransferase elevations that occur during chronic therapy with acetaminophen are rarely symptomatic, generally go undetected, resolve rapidly with discontinuation of acetaminophen and sometimes even with continuation at the same dose. Such transient aminotransferase elevations do not appear to have lasting effects on the liver but can cause diagnostic confusion and lead to expensive or invasive interventions. Acetaminophen overdose, in contrast, can cause a serious acute liver injury and hepatic failure that can result in

death or need for emergency liver transplantation. Currently, acetaminophen is the major cause of acute liver failure in the United States, Europe and Australia. The liver injury from acetaminophen can be prevented or ameliorated by repletion of glutathione levels which can be accomplished with n-acetylcysteine (NAC), which is available in oral and intravenous forms and should be administered immediately upon diagnosis of acetaminophen overdose. A nomogram (Rumack-Matthew Nomogram) to calculate the likelihood of liver injury from acetaminophen is available that plots acetaminophen plasma concentrations against the number of hours post-ingestion that the sample was taken. Patients with plasma levels above the “treatment line” should receive either oral or intravenous NAC. Details of administration and assistance can be obtained from the U.S. National Poison Center: 1-800-222-1222. Patients who recover spontaneously from acetaminophen hepatotoxicity generally return to normal health without evidence of chronic liver injury. The nomogram is less accurate in assessing risk with chronic or unintentional overdose. Recently, tests for acetaminophen adducts have been developed that accurately reflect hepatic damage from acetaminophen overdose and are detectable after plasma acetaminophen levels fall into undetectable range. Thus, the presence of acetaminophen adducts supports the diagnosis and their absence is a reliable in excluding acetaminophen as a cause of acute liver injury (if ALT levels are still elevated).

Drug Class: **Nonsteroidal Antiinflammatory Drugs**

CASE REPORTS

Case 1. Transient serum aminotransferase elevations due to pharmacologic doses of acetaminophen.

[Modified from: Watkins PB, Kaplowitz N, Slattery JT, Colonese CR, Colucci SV, Stewart PW, Harris SC. Aminotransferase elevations in healthy adults receiving 4 grams of acetaminophen daily: a randomized controlled trial. JAMA 2006; 296: 87-93. [PubMed Citation](#)]

A healthy volunteer was started on acetaminophen in a dose of 4 grams daily as a part of a randomized controlled study of the pharmacokinetics and safety of acetaminophen combinations. After 4 days, serum ALT levels began to rise and acetaminophen was stopped on day 7 when ALT levels rose above 3-fold elevated (Table). ALT levels continued to rise, peaking at a level of 575 U/L on day 11 and slowly decreasing thereafter. The patient had no history of liver disease, tested negative for hepatitis virus markers and remained asymptomatic.

Key Points

Medication:	Acetaminophen (4 g daily)
Pattern:	Hepatocellular (R=14) [alkaline phosphatase levels normal]
Severity:	Mild (ALT elevations without jaundice)
Latency:	7 days
Recovery:	~2 weeks
Other medications:	None

Laboratory Values

Days After Starting	Days After Stopping	ALT (U/L)	Acetaminophen Levels (mg/dL)	Other
0				
1		35	0	
2		35	4.0	

Table continued from previous page.

Days After Starting	Days After Stopping	ALT (U/L)	Acetaminophen Levels (mg/dL)	Other
3		35	4.5	
4		45	4.0	
5		70	3.5	
6		80		
7	0	135	3.0	Acetaminophen stopped
8	1	310		
9	2	470	0	
10	3	490		
11	4	575	0	
12	5	520		
13	6	420	0	
14	7	330		
15	8	260		
17	9	160		
18	10	130		
19	11	105		
Normal Values		<40	0	

*Estimated from Figure 3.

Comment

In this carefully designed and monitored, prospective, randomized controlled trial of acetaminophen therapy, 81 of 106 patients (76%) receiving acetaminophen in doses of 4 grams daily by mouth developed at least one elevation in ALT above the upper limit of normal (ULN) (i.e., >40 U/L); in 53% ALT levels peaked at greater than 2 times ULN (>80 U/L), 39% greater than 3 times (>120 U/L), 25% greater than 5 times (>200 U/L), and 8% greater than 8 times (>320 U/L). The case shown above had one of the highest elevations observed in the study. Typically, ALT levels began to rise after 3 to 7 days and remained elevated for 1 to 11 days. No patient became jaundiced and there were no clear symptoms associated with the elevations. Patients with ALT levels rising above 3 times ULN had acetaminophen stopped, but enzyme levels continued to rise for a few days as in this patient, whose ALT level was 575 U/L 5 days after stopping drug, and at a point that acetaminophen levels were undetectable. Thus, asymptomatic ALT elevations may be caused by high therapeutic doses of acetaminophen even when plasma levels are undetectable. Partially in response to this study, recommendations were made that acetaminophen be limited to no more than 3 grams daily.

Case 2. Severe acute acetaminophen hepatotoxicity after an intentional overdose.

[Acute Liver Failure Study Group Patient #2281]

A 27 year old woman took an overdose of acetaminophen (30 tablets of 325 mg each) in a suicide attempt because of a failed relationship. The following day she was nauseated and vomited several times, but she waited another day before presenting to an emergency room, approximately 48 hours after the ingestion. She had no other significant medical problems, and denied a history of liver disease, alcohol abuse or risk factors for viral

hepatitis. On presentation, she was oriented but drowsy. Her vital signs included pulse of 125/min, BP 100/65, respirations 25/min and temperature 37 °C. She was mildly jaundiced, but had no rash or signs of chronic liver disease. The total serum bilirubin level was 4.4 mg/dL, ALT 3,570 U/L, AST 7,377 U/L, and alkaline phosphatase 109 U/L (Table). A urine toxicology screen was positive for benzodiazepines and cocaine. Serum acetaminophen levels were 31 mcg/mL, and serum acetaminophen adducts were positive (23.8 nmol/mL). She was admitted to the intensive care unit and given intravenous N-acetylcysteine. Tests for hepatitis A, B and C were negative as were autoantibodies. Abdominal ultrasound showed no evidence of biliary obstruction. Over the next few days, she had mild hepatic encephalopathy. She was placed on a liver transplantation waiting list, but began to improve spontaneously, and was transferred to a psychiatric service after a week in the hospital. When finally discharged several weeks later, all liver tests had returned to normal.

Key Points

Medication:	Acetaminophen (~10 g as a single overdose)
Pattern:	Hepatocellular (R=~100)
Severity:	Severe (jaundice, encephalopathy and INR prolongation)
Latency:	2 days
Recovery:	~2 weeks
Other medications:	Possibly cocaine and benzodiazepines

Laboratory Values

Days After Ingestion	ALT (U/L)	Bilirubin (mg/dL)	INR	Other
2	3570	4.4	6.9	Admission
3	7372	4.2	6.6	Encephalopathy
4	5139	4.7	4.0	
5	2852	5.6	3.7	
6	1764	6.3	3.0	
7	1478	8.0	3.2	
8	828	9.9	2.1	Transferred
Normal	<42	<1.2	<1.2	

Comment

Acetaminophen hepatotoxicity typically presents within 2 to 5 days of an intentional overdose, with a pattern of acute hepatocellular necrosis with striking elevations of aminotransferase levels (often above 2000 U/L and higher than typically seen with acute viral hepatitis) and signs of hepatic failure (INR elevations) despite minimal or no jaundice. Lactic dehydrogenase values are also markedly elevated. Jaundice typically worsens over the first few days, while signs of hepatic failure may improve (encephalopathy and coagulopathy). Patients may also have renal insufficiency. Late presentation (>48 hours) after a suicidal overdose is associated with severe toxicity, while early presentation (<12 to 24 hours) is associated with milder degrees or no liver injury provided the antidote, N-acetylcysteine, is given promptly on arrival.

Case 3. Severe acetaminophen hepatotoxicity after unintentional overdose.

[Acute Liver Failure Study Group Patient #2748]

A 69 year old woman with chronic headaches taking high doses of acetaminophen and other analgesics and over-the-counter products developed drowsiness, poor appetite, nausea, vomiting and mild diarrhea. She was brought to the emergency room by her daughter who found her mother to be confused and not her usual highly functioning self. She had a history of mitral regurgitation and was taking warfarin chronically. She had no history of liver disease, alcohol use or risk factors for viral hepatitis. Medications being taken included Tylenol, Tylenol Sinus, Vicodin, and tramadol, but the amounts being taken were not clear. The patient and her daughter denied that she was suicidal. On admission, serum acetaminophen levels were 133 mg/dL. On examination, she was confused and had asterixis. Vital signs included pulse of 136/min, respirations 18/min, BP 127/64 and temperature 36.5 °C. She had no signs of chronic liver disease. Serum bilirubin was 4.8 mg/dL, ALT 5,945 U/L, AST 12,476 U/L and alkaline phosphatase was normal (Table). Tests for hepatitis A and B were negative as were autoantibodies. She had antibody to hepatitis C; HCV RNA testing was not performed. Abdominal ultrasound showed no evidence of biliary obstruction. She was given intravenous N-acetylcysteine and vitamin K. Within 2 days she began to improve clinically, and she was discharged after 7 days. In follow up 2 weeks later, all liver tests were normal and warfarin was restarted.

Key Points

Medication:	Acetaminophen (uncertain doses)
Pattern:	Hepatocellular (R>100) [alkaline phosphatase levels normal]
Severity:	Severe (jaundice, hospitalization and signs of hepatic failure)
Latency:	5-7 days
Recovery:	~2 weeks
Other medications:	Warfarin, tramadol, and oxycodone

Laboratory Values

Days After Stopping	ALT (U/L)	Bilirubin (mg/dL)	INR	Other
0	5945	4.8	3.7	Asterixis
1	4675	7.0	4.7	
2	3744	8.4	3.7	
3	1688	10.1	3.1	Improved mentation
4	1365	11.1	2.9	
5	855	12.1	2.6	
6	630	12.2	2.0	Discharged
Normal	<42	<1.2	<1.2	

Comment

An example of unintentional or accidental acetaminophen overdose or “therapeutic misadventure” in an elderly lady who was taking several forms of acetaminophen over several days. Contributing factors may have been chronic hepatitis C, but the pattern of serum enzyme elevations and clinical course were typical of acetaminophen overdose and not likely to be due to acute viral hepatitis. While intentional overdoses are associated with ingestion of at least 10 grams of acetaminophen at one time, unintentional overdoses are usually found with ingestion of somewhat lower amounts over a 3 to 5 day period, particularly in patients with malnutrition, alcoholism, chronic liver disease or an accompanying medical illness. Cases are frequently associated with use of narcotic combinations (such as hydrocodone with acetaminophen), with abuse of the

narcotic leading to increasing acetaminophen exposure. Finally, in many situations such as this case, the actual amount of acetaminophen ingested is unclear.

PRODUCT INFORMATION

REPRESENTATIVE TRADE NAMES

Acetaminophen – Generic, Various Trade Names

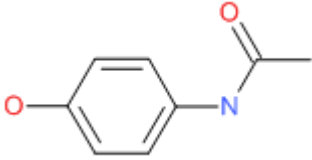
DRUG CLASS

Nonsteroidal Antiinflammatory Drugs

COMPLETE LABELING

Product labeling at DailyMed, National Library of Medicine, NIH

CHEMICAL FORMULA AND STRUCTURE

DRUG	CAS REGISTRY NUMBER	MOLECULAR FORMULA	STRUCTURE
Acetaminophen	103-90-2	C ₈ H ₉ N-O ₂	

ANNOTATED BIBLIOGRAPHY

References updated: 28 January 2016

Zimmerman HJ. Acetaminophen (Paracetamol). In, Zimmerman HJ. Hepatotoxicity: the adverse effects of drugs and other chemicals on the liver. 2nd ed. Philadelphia: Lippincott, 1999, pp. 271-4 and 540-1.

(Expert review of acetaminophen hepatotoxicity published in 1999).

Hinson JA. Mechanisms of acetaminophen-induced liver disease. In, Kaplowitz N, DeLeve LD, eds. Drug-induced liver disease. 3rd ed. Amsterdam: Elsevier, 2013, pp. 305-30.

(Review of the mechanisms of liver cell injury due to acetaminophen published in 2007).

James LP. Acetaminophen. In, Kaplowitz N, DeLeve LD, eds. Drug-induced liver disease. 3rd ed. Amsterdam: Elsevier, 2013, pp. 331-42.

(Review of the clinical and pathological features and diagnosis of acetaminophen-hepatotoxicity).

Grosser T, Smyth E, FitzGerald GA. Para-Aminophenol derivatives: acetaminophen. Anti-inflammatory, antipyretic and analgesic agents; pharmacology of gout. In, Brunton LL, Chabner BA, Knollman BC, eds. Goodman & Gilman's the pharmacological basis of therapeutics. 12th ed. New York: McGraw-Hill, 2011, pp. 982-4.

(Textbook of pharmacology and therapeutics).

Davidson DG, Eastham WN. Acute liver necrosis following overdose of paracetamol. Br Med J 1966; 2: 497-9. PubMed PMID: 5913083.

(Two cases of fatal acute liver failure with hypoglycemia after acetaminophen overdose [17 and 50 g]; marked centrilobular hepatic necrosis found histologically: early report).

Thompson JS, Prescott LF. Br Med J 1966; 2: 506-7. PubMed PMID: 5913085.

(54 year old man took an overdose of ~23 g of acetaminophen and developed drowsiness followed by jaundice 6 days later [bilirubin 4.4 mg/dL, ALT 124 U/L], recovering spontaneously: early report).

Clark R, Borirakchanyavat V, Davidson AR, Thompson RP, Widdop B, Goulding R, Williams R. Hepatic damage and death from overdose of paracetamol. Lancet 1973; 1: 66-70. PubMed PMID: 4118649.

(Among 60 patients with acetaminophen overdose, 49 developed liver damage, 17 hepatic failure, and 12 died. Biopsies showed centrilobular necrosis and collapse; prognosis correlated with protime and bilirubin levels; increasing number of cases were found between 1966 and 1971).

Mitchell JR, Thorgeirsson SS, Potter WZ, Jollow DJ, Keiser H. Acetaminophen-induced hepatic injury: protective role of glutathione in man and rationale for therapy. Clin Pharmacol Ther 1974; 16: 676-84. PubMed PMID: 4417718.

(Analysis of metabolites of acetaminophen in humans and mice; mercapturic acid ordinarily detoxified by conjugation to glutathione; study demonstrating basis for use of glutathione-like nucleophiles for acetaminophen toxicity).

McJunkin B, Barwick KW, Little WC, Winfield JB. Fatal massive hepatic necrosis following acetaminophen overdose. JAMA 1976; 236: 1874-5. PubMed PMID: 989539.

(24 year old woman took overdose of 13 g of acetaminophen and developed acute liver failure and death in 7 days [bilirubin 11.9 mg/dL, AST 8795 U/L, Alk P 189 U/L, LDH >2400 U/L, protime 72 sec]; early report from US).

Ambre J, Alexander M. Liver toxicity after acetaminophen ingestion. Inadequacy of the dose estimate as an index of risk. JAMA 1977; 238: 500-1. PubMed PMID: 577576.

(Clinical history of amount of acetaminophen ingested may be inaccurate; 5 cases in which a significant overdose was reported by the patient with only low levels of acetaminophen found in plasma and no subsequent liver injury).

Rumack BH, Peterson RG. Acetaminophen overdose: incidence, diagnosis, and management in 416 patients. Pediatrics 1978; 62(5 Pt 2 Suppl): 898-903. PubMed PMID: 724342.

(Nationwide multicenter study identified 25% of acetaminophen overdoses [112/416] as having "toxic" levels; no deaths among 100 patients treated with N-acetylcysteine within 24 hours of ingestion).

Licht H, Seeff LB, Zimmerman HJ. Apparent potentiation of acetaminophen hepatotoxicity by alcohol. Ann Intern Med 1980; 92: 511-6. PubMed PMID: 7362155.

(53 year old alcoholic man with chronic intermittent use of 2.5-3.9 g of acetaminophen daily developed acute liver injury and ascites [bilirubin 13 mg/dL, ALT 4560 U/L, protime 22 sec], recovering spontaneously).

Rumack BH, Peterson RG, Koch GG, Amara IA. Acetaminophen overdose: 662 cases with evaluation of oral acetylcysteine treatment. Arch Intern Med 1981; 141: 380-5. PubMed PMID: 7469629.

(Among 662 patients with acetaminophen overdose in a national open-clinic study, no deaths occurred if N-acetylcysteine [NAC] was given within 24 hours; among those with toxic levels, AST elevations above 1000 U/L occurred in 7% given NAC within 10 hours, 29% at 10-16 hours, and 62% at 16-24 hours).

Black M, Cornell JF, Rabin L, Shachter N. Late presentation of acetaminophen hepatotoxicity. Dig Dis Sci 1982; 27: 370-4. PubMed PMID: 7067588.

- (37 year old woman with chronic alcoholism took 10 g acetaminophen daily for several weeks and developed acute liver failure [bilirubin 3.9 rising to 19 mg/dL, AST 13,350 U/L] and death; recognition of role of acetaminophen was delayed; autopsy showed centrilobular necrosis and steatohepatitis).*
- Byer AJ, Traylor TR, Semmer JR. Acetaminophen overdose in the third trimester of pregnancy. JAMA 1982; 247: 3114-5. PubMed PMID: 7077806.
- (26 year old woman took overdose of acetaminophen [22.5 g] at 36 weeks gestation and was given N-acetylcysteine within <10 hours and had no subsequent ALT elevations; uneventful delivery and normal child 6 weeks later).*
- Benson GD. Acetaminophen in chronic liver disease. Clin Pharmacol Ther 1983; 33: 95-101. PubMed PMID: 6848304.
- (Six patients with chronic liver disease were given 4.0 g/day of acetaminophen for 5 days without evidence of drug accumulation or ALT elevations; 20 patients given 4 g acetaminophen or placebo for 13 days, with no differences in two groups).*
- Haibach H, Akhter JE, Muscato MS, Cary PL, Hoffmann MF. Acetaminophen overdose with fetal demise. Am J Clin Pathol 1984; 82: 240-2. PubMed PMID: 6465090.
- (24 year old woman presented 15-39 hours after overdose of acetaminophen at 28 week gestation [bilirubin not given, ALT 1410 rising to 4521 U/L], and dead fetus, autopsy of infant showing massive "cytolysis").*
- Rumack BH. Acetaminophen overdose in young children: treatment and effects of alcohol and other additional ingestants in 417 cases. Am J Dis Child 1984; 138: 428-33. PubMed PMID: 6711498.
- (417 children with acetaminophen overdose in multicenter study; 55 with a toxic level; 43 treated with N-acetylcysteine; no deaths; those with other ingestants had more lethargy and higher AST levels).*
- Seeff LB, Cuccherini BA, Zimmerman HJ, Adler E, Benjamin SB. Acetaminophen hepatotoxicity in alcoholics. A therapeutic misadventure. Ann Intern Med 1986; 104: 399-404. PubMed PMID: 3511825.
- (6 case reports and review of 19 cases in literature on acetaminophen toxicity in alcoholics taking 2.6-16.5 g daily for pain or fever [bilirubin 1.3-35 mg/dL, AST 2870-26,900 U/L], all survived).*
- Smilkstein MJ, Knapp GL, Kulig KW, Rumack BH. Efficacy of oral N-acetylcysteine in the treatment of acetaminophen overdose: analysis of the National Multicenter Study(1976-1985). N Engl J Med 1988; 319: 1557-62. PubMed PMID: 3059186.
- (Results of multicenter trial of 2540 patients with acetaminophen overdose given NAC: 28 deaths due to acetaminophen, but none among those given N-acetylcysteine [NAC] less than 16 hours after overdose; rate of ALT >1000 U/L was 6% if NAC given within 10 hours, 26% if between 10 and 24 hours after ingestion).*
- Foust RT, Reddy KR, Jeffers LJ, Schiff ER. Nyquil-associated liver injury. Am J Gastroenterol 1989; 84: 422-5. PubMed PMID: 2929565.
- (56 year old man and 37 year old woman developed acute liver failure after ingestion of bottle of Nyquil [420 mL: 14 g acetaminophen in 25% alcohol] over 1-3 days [bilirubin 1.3 and 12.5 mg/dL, AST 8285 and 2413 U/L, Alk P 249 and 53 U/L], both survived).*
- Harrison PM, Keays R, Bray GP, Alexander GJM, Williams R. Improved outcome of paracetamol-induced fulminant hepatic failure by late administration of acetylcysteine. Lancet 1990; 335: 1572-3. PubMed PMID: 1072496.
- (Retrospective analysis of 100 patients with acetaminophen induced acute liver failure found lower mortality in those receiving N-acetylcysteine [NAC] 10-36 hours after overdose than controls [37% vs 58%], suggesting beneficial effects of NAC even if given somewhat late).*

Wootton FT, Lee WM. Acetaminophen hepatotoxicity in the alcoholic. *South Med J* 1990; 83: 1047-9. PubMed PMID: 2402650.

(In retrospective review from a single center over 2 years, 7 cases of suspected acetaminophen hepatotoxicity were identified among alcoholics taking high or super-therapeutic doses [3.5-11 g daily for 2-6 days], all with high AST [4472-21660 U/L] and 3 fatal).

Keays R, Harrison PM, Wendon JA, Forbes A, Gove C, Alexander GJM, Williams R. Intravenous acetylcysteine in paracetamol induced fulminant hepatic failure: a prospective controlled trial. *BMJ* 1991; 303: 1026-9. PubMed PMID: 1954453.

(Randomized controlled trial of intravenous N-acetylcysteine [NAC] vs no therapy in 50 patients with acute liver failure 36 to 80 hours after acetaminophen overdose found improved survival [48% vs 20%] and less cerebral edema, suggesting that late administration of NAC is partially effective).

Whitcomb DC, Block GD. Association of acetaminophen hepatotoxicity with fasting and ethanol use. *JAMA* 1994; 272: 1845-50. PubMed PMID: 7990219.

(Retrospective analysis of 49 patients presenting with acetaminophen hepatotoxicity at single center over 7 years; 43% of cases were unintentional with doses of 4-10 g daily, often in context of recent fasting rather than alcoholism).

Cassidy WM, Reynolds TB. Serum lactic dehydrogenase in the differential diagnosis of acute hepatocellular injury. *J Clin Gastroenterol* 1994; 19: 118-21. PubMed PMID: 7963356.

(Retrospective review of 97 cases of acute liver injury for lactic dehydrogenase [LDH] levels; marked and similar elevations of LDH and ALT or AST found in ischemic hepatitis and acetaminophen toxicity compared to viral hepatitis).

Bonkovsky HL, Kane RE, Jones DP, Galinsky RE, Banner B. Acute hepatic and renal toxicity from low doses of acetaminophen in the absence of alcohol abuse or malnutrition: evidence for increased susceptibility to drug toxicity due to cardiopulmonary and renal insufficiency. *Hepatology* 1994; 19: 1141-8. PubMed PMID: 8175135.

(67 year old man with severe pulmonary and cardiovascular disease developed acute liver injury after taking 1-3 g of acetaminophen daily for 2 days [bilirubin 2.7 mg/dL, ALT 2175 U/L, LDH 3125 U/L, Alk P 130 U/L], resolving rapidly; role of acute ischemic hepatitis could not be excluded).

Makin AJ, Wendon J, Williams R. A 7-year experience of severe acetaminophen-induced hepatotoxicity (1987-1993). *Gastroenterology* 1995; 109: 1907-16. PubMed PMID: 7820317.

(7 year experience from King's College Hospital acute liver failure group of 560 patients with acetaminophen hepatotoxicity, rate increased over time [58 to 123 cases yearly], but survival improved [<50% to 78%] while use of N-acetylcysteine [NAC] [40% to 83%] and transplant [1 to 13 per year] increased; 8% were considered accidental or unintentional).

Alonso EM, Sokol RJ, Hart J, Tyson RW, Narkewicz MR, Whittington PF. Fulminant hepatitis associated with centrilobular hepatic necrosis in young children. *J Pediatr* 1995; 127: 888-94. PubMed PMID: 8523184.

(7 children with prodrome of viral illness followed by encephalopathy, liver injury, mild jaundice and centrilobular necrosis; cause was not identified, but authors thought that course was worsened by acetaminophen).

Zimmerman HJ, Maddrey WC. Acetaminophen (paracetamol) hepatotoxicity with regular intake of alcohol: analysis of instances of therapeutic misadventure. *Hepatology* 1995; 22: 767-73. PubMed PMID: 7657281.

(Analysis of 67 patients enrolled in registry of alcoholic patients with unintentional acetaminophen toxicity usually taking it for pain or fever, in doses of <4 to >15 g daily for 1 to 30 days; 18% fatal; AST >3000 U/L in 90%; similar features in 94 cases in literature).

Schiodt FV, Rochling FA, Casey DL, Lee WM. Acetaminophen toxicity in an urban county hospital. *N Engl J Med* 1997; 337: 1112-7. PubMed PMID: 9329933.

(Retrospective analysis of 71 patients admitted to Parkland Memorial Hospital, Dallas for acetaminophen overdose between 1992-5 found 50 due to single suicidal dose and 21 due to unintentional overdose, typically while attempting to control pain. Accidental cases were more severe, older, more likely alcoholic, more often using other analgesics and had higher mortality rate [19% vs 2%]).

Johnston SC, Pelleier LL, Jr. Enhanced hepatotoxicity of acetaminophen in the alcoholic patient: two case reports and a review of the literature. *Medicine (Baltimore)* 1997; 76: 185-91. PubMed PMID: 9193453.

(43 year old male and 46 year old female alcoholic taking 7.1 and 7.7 g acetaminophen over 24 hours for pain developed acute liver failure and died [bilirubin 13 mg/dL and not given, AST 8,685 and 14,000 U/L, protime 32.8 and 44.2 sec]; literature review of 51 cases of unintentional acetaminophen overdose in alcoholics).

Thomas SH, Horner JE, Chew K, Connolly J, Dorani B, Bevan L, Bhattacharyya S, et al. Paracetamol poisoning in the north east of England: presentation, early management and outcome. *Hum Exp Toxicol* 1997; 16: 495-500. PubMed PMID: 9306135.

(Among 400 presentations of acute acetaminophen overdose, serum levels at 4 hours correlated only weakly with reported dose and were above the nomogram treatment line in 20% of those who reported taking more than 12 g and in 3% of those taking less).

Andrade RJ, Lucena MI, Garcia-Escano D, Camargo R. Severe idiosyncratic acute hepatic injury caused by paracetamol. *J Hepatol* 1998; 28: 1078. PubMed PMID: 9672188.

(29 year old woman developed jaundice [bilirubin 13.9 mg/dL, ALT 945 U/L, Alk P 532 U/L] 11 days after 7 day course of roxithromycin and acetaminophen [1.5 g daily], recovering in 2 months; restarting acetaminophen [~1 g/day for 2 days] was followed by acute rise in ALT to 3216 U/L but normal bilirubin, resolving rapidly; interpreted initial episode as due to roxithromycin, with increased susceptibility to acetaminophen during recovery).

Gow PJ, Smallwood RA, Angus PW. Paracetamol overdose in a liver transplantation centre: an 8-year experience. *J Gastroenterol Hepatol* 1999; 14: 817-21. PubMed PMID: 10482436.

(Retrospective review of 152 patients with acetaminophen overdose from an Australian center found increasing rate in population, 29 patients had hepatotoxicity, 13 developed acute liver failure, one had liver transplant and subsequently died, no other fatalities).

Bond GR, Hite LK. Population-based incidence and outcome of acetaminophen poisoning by type of ingestion. *Acad Emerg Med* 1999; 6: 115-20. PubMed PMID: 10569383.

(Retrospective analysis of patients admitted to four hospitals over 4 years; 137 cases of acetaminophen overdose, 5.5 per 100,000 person-years, rarely serious and often too late for use of nomogram).

Alander SW, Dowd MD, Bratton SL, Kearns GL. Pediatric acetaminophen overdose: risk factors associated with hepatocellular injury. *Arch Pediatr Adolesc Med* 2000; 154: 346-50. PubMed PMID: 10768670.

(Retrospective analysis of 322 children with acetaminophen overdose from two centers between 1988 and 1997; ALT elevations in 8%, liver failure in 4 [1%], and 1 death; overdose was unintentional in 54% [ages 2 months to 13 years], only one case of which led to liver injury [0.6%] and none to liver failure).

Broughan TA, Soloway RD. Acetaminophen hepatotoxicity. *Dig Dis Sci* 2000; 45: 1553-8. PubMed PMID: 11007105.

(Retrospective chart review found 48 cases of acetaminophen hepatotoxicity admitted to single hospital over 7 year period: 8 unintentional; 2 fatalities, 1 transplanted).

Caravati EM. Unintentional acetaminophen ingestion in children and the potential for hepatotoxicity. Clin Toxicol 2000; 38: 291-6. PubMed PMID: 10866329.

(Prospective evaluation of 1015 children with single acetaminophen overdose of >140 mg/kg; only 8 [ages 1-2 years] had potentially hepatotoxic plasma levels, all had received >200 mg/kg [5 received adult formulation], suggesting that lower ingestions can be treated at home).

Cranswick N, Coghlan D. Paracetamol efficacy and safety in children: the first 40 years. Am J Ther 2000; 7: 135-41. PubMed PMID: 11319581.

(Review of use, efficacy and safety of acetaminophen in children).

Ostapowicz G, Lee WM. Acute hepatic failure: a Western perspective. J Gastroenterol Hepatol 2000; 15: 480-8. PubMed PMID: 10847432.

(Review of acute liver failure contrasting experience in different areas of the world, more diverse causes in the West including drug induced liver disease in 7-16%, acetaminophen 58% in the UK and 20% in US, but <2% in France, Australia and India).

Halevi A, Ben-Amitai D, Garty BZ. Toxic epidermal necrolysis associated with acetaminophen ingestion. Ann Pharmacother 2000; 34: 32-4. PubMed PMID: 10669183.

(7 year old girl developed toxic epidermal necrolysis [TEN] 12 hours after receiving 3 doses of acetaminophen for fever and sore throat [eosinophils 8%, bilirubin not given, ALT 88 U/L, AST 55 U/L, CK 1660 U/L], later developing erythema, urticaria, fever and hypotension 30 minutes after a single challenge dose).

Makin A, Williams R. Paracetamol hepatotoxicity and alcohol consumption in deliberate and accidental overdose. Q J Med 2000; 93: 314-9. PubMed PMID: 10873183.

(Retrospective analysis of 553 case of acetaminophen hepatotoxicity seen at King's College Hospital over 7 years, 38 [7%] were unintentional, alcohol use more common with accidental overdose but heavy use more common in suicidal group; no correlation of alcohol with severity).

Kuffner EK, Dart RC, Bogdan GM, Hill RE, Casper E, Darton L. Effect of maximal daily doses of acetaminophen on the liver of alcoholic patients: a randomized, double-blind, placebo-controlled trial. Arch Intern Med 2001; 161: 2247-52. PubMed PMID: 11575982.

(201 patients enrolled in randomized controlled trial of 4 g of acetaminophen for 2 days in patients entering alcohol rehabilitation program found no significant changes in ALT or AST levels, minor elevations were similar in frequency in both groups).

Bareille MP, Montastruc JL, Lapeyre-Mestre M. [Liver damage and nonsteroidal anti-inflammatory drugs: case non-case study in the French Pharmacovigilance Database] Therapie 2001; 56: 51-5. French. PubMed PMID: 11322018.

(Comparing adverse event reports designated as liver related or not found increased rate of liver related reports attributed to acetaminophen).

Caravati EM. Safety of childhood acetaminophen overdose. Ann Emerg Med 2001; 37: 114-6. PubMed PMID: 11145785.

(Letter raising the issue of minimum acute hepatotoxic dose of acetaminophen in children suggesting that 200 mg/kg may be too high).

Farooqi VA, Khokhar N. Paracetamol poisoning resulting in massively raised serum transaminases. J Pak Med Assoc 2001; 51: 303-4. PubMed PMID: 11715899.

(45 year old British woman took 15 g overdose of acetaminophen while visiting in Pakistan and presented with ALT values of 1121 U/L, rising to 14,544 2 days later; given N-acetylcysteine and recovered).

- Ganry H, Pruvot F, Vesque D, Schmidely N. [Liver and renal tolerance to paracetamol: 3 g or 4 g per day?]. *Presse Med* 2001; 30: 724-30. French. PubMed PMID: 1136073.
- James LP, Wilson JT, Simar R, Farrar HC, Kearns GL, Simposon PM, Hinson JA, et al., Pediatric Pharmacology Research Unit Network. Evaluation of occult acetaminophen hepatotoxicity in hospitalized children receiving acetaminophen. *Clin Pediatr(Phila)* 2001; 40: 243-8. PubMed PMID: 11388672.
- (Acetaminophen adducts were highly specific for acetaminophen induced hepatic injury in animal models; immunoblot assay for adducts however, identified them in only 1 of 12 children with hepatotoxicity after overdose).*
- Shinzawa H, Togashi H, Sugahara K, Ishibashi M, Terui Y, Aoki M, Mitsuhashi H, et al. Acute cholestatic hepatitis caused by a probable allergic reaction to paracetamol in an adolescent. *Tohoku J Exp Med* 2001; 193: 255-8. PubMed PMID: 11315774.
- (14 year old girl developed rash and acute liver injury after few days of acetaminophen, but also taking midocamycin [bilirubin 2.4 rising to 12.4 mg/dL, ALT 512 U/L, Alk P 1930 U/L, 12% eosinophilia], suffering prolonged jaundice which required prednisone therapy; positive lymphocyte stimulation test to acetaminophen).*
- Sztajnkrzyer MJ, Bond GR. Chronic acetaminophen overdosing in children: risk assessment and management. *Curr Opin Pediatr* 2001; 13: 177-82. PubMed PMID: 11317062.
- (Review of diagnosis and management of acetaminophen overdose in children).*
- Gill EJ, Contos MJ, Peng TC. Acute fatty liver of pregnancy and acetaminophen toxicity leading to liver failure and postpartum liver transplantation. A case report. *J Reprod Med* 2002; 47: 584-6. PubMed PMID: 12170538.
- (18 year old woman with acute fatty liver of pregnancy at 33 weeks gestation with fetal death and hepatic failure [ALT 4112 U/L] and vague history of acetaminophen intake; liver biopsy showed both centrolobular necrosis and microvesicular fatty change; patient underwent liver transplantation).*
- Prandota J. Important role of prodromal viral infections responsible for inhibition of xenobiotic metabolizing enzymes in the pathomechanism of idiopathic Reye's syndrome, Stevens-Johnson syndrome, autoimmune hepatitis, and hepatotoxicity of the therapeutic doses of acetaminophen used in genetically predisposed persons. *Am J Ther* 2002; 9: 149-56. PubMed PMID: 11897929.
- (Review article suggesting that viral infections may predispose to several syndromes including Reye and Stevens Johnson syndrome, autoimmune hepatitis, and acetaminophen hepatotoxicity).*
- Gyamlani GG, Parikh CR. Acetaminophen toxicity: suicidal vs. accidental. *Crit Care* 2002; 6: 155-9. PubMed PMID: 11983042.
- (Among 93 patients with acetaminophen toxicity seen over 52 month period, 13 were accidental and levels were not as predictive of liver injury as in 80 suicidal cases; 2 deaths in accidental group).*
- Lukasik-Glebocka M, Klimaszuk D. [Alcohol-paracetamol syndrome: a case report] *Przegl Lek* 2002; 59: 381-3. Polish. PubMed PMID: 1218401.
- Ostapowicz G, Fontana RJ, Schiodyt FV, Larson A, Davern TJ, Han SH, McCashland TM, et al.; U.S. Acute Liver Failure Study Group. Results of a prospective study of acute liver failure at 17 tertiary care centers in the United States. *Ann Intern Med* 2002; 137: 947-54. PubMed PMID: 12484709.
- (Analysis of 308 cases of acute liver failure seen at 17 centers over 3.5 year period; acetaminophen was cause of 38%; in comparison to others, patients with acetaminophen injury were typically younger, more often white, had higher survival without transplant [68%], shorter time from jaundice to encephalopathy, higher mean ALT and AST levels and lower bilirubin levels).*

Rumack BH. Acetaminophen hepatotoxicity: the first 35 years. *J Toxicol Clin Toxicol* 2002; 40: 3-20. PubMed PMID: 11990202.

(Personal review of development of the nomogram for acetaminophen hepatotoxicity and its therapy with N-acetylcysteine, evolution of understanding of the mechanism of liver injury, the role of CPY2E1 and issues in interpretation of acetaminophen ingestion history and plasma levels).

Schmidt LE, Dalhoff K. Serum phosphate is an early predictor of outcome in severe acetaminophen-induced hepatotoxicity. *Hepatology* 2002; 36: 659-65. PubMed PMID: 12198658.

(High phosphate levels were more common among patients with acetaminophen hepatotoxicity and among fatal than nonfatal cases, perhaps reflecting renal insufficiency).

Schiødt FV, Lee WM, Bondesen S, Ott P, Christensen E. Influence of acute and chronic alcohol intake on the clinical course and outcome in acetaminophen overdose. *Aliment Pharmacol Ther* 2002; 16: 707-15. [PubMed Citation](#)

(Among 209 patients admitted to Copenhagen hospital with acetaminophen overdose between 1993-6, analysis showed that chronic alcohol intake and delay to N-acetylcysteine [NAC] treatment were associated with severe course, but only delay to NAC with decreased survival).

Bolesta S, Haber SL. Hepatotoxicity associated with chronic acetaminophen administration in patients with risk factors. *Ann Pharmacother* 2002; 36: 331-3. PubMed PMID: 11847957.

(Literature review found 4 case reports of liver toxicity with acetaminophen doses of <4 g daily and no risk factors; these instances were marked mostly by AST elevations only and several had other possible causes of liver disease).

Kurtovic J, Riordan SM. Paracetamol-induced hepatotoxicity at recommended dosage. *J Intern Med* 2003; 253: 240-3. PubMed PMID: 12542566.

(53 year old woman on chemotherapy, who had malnutrition and was fasting, developed acute hepatic injury on acetaminophen 4 g daily while in hospital [bilirubin 1.8 mg/dL, ALT 5920 U/L, Alk P 169 U/L], resolving with NAC therapy; no recurrence on rechallenge with lower doses).

Fukumoto M. [Acetaminophen poisoning] *Chudoku Kenkyu* 2003; 16: 285-97. Japanese. PubMed PMID: 1458235.

Heaton PC, Cluxton RJ Jr, Moomaw CJ. Acetaminophen overuse in the Ohio Medicaid population. *J Am Pharm Assoc* 2003; 43: 680-4. PubMed PMID: 14717264.

(Analysis of Medicaid claims data demonstrating that 3% of prescriptions were for high therapeutic doses of acetaminophen in patients with liver disease).

James LP, Mayeux PR, Hinson JA. Acetaminophen-induced hepatotoxicity. *Drug Metab Dispos* 2003; 31: 1499-506. PubMed PMID: 14625346.

(Review of metabolism of acetaminophen and mechanisms of hepatotoxicity).

Kociancic T, Reed MD. Acetaminophen intoxication and length of treatment: how long is long enough? *Pharmacotherapy* 2003; 23: 1052-9. PubMed PMID: 12921251.

(Current regimen of oral NAC is 140 mg/kg followed by 70 mg/kg every 4 hours for 17 doses [total of 72 hours]; shorter courses would be easier and less expensive).

McGregor AH, More LJ, Simpson KJ, Harrison DJ. Liver death and regeneration in paracetamol toxicity. *Hum Exp Toxicol* 2003; 22: 221-7. PubMed PMID: 12755473.

(Histology of acetaminophen hepatotoxicity reveals apoptosis in 0.6% of cells, suggesting role of programmed cell death in injury).

- Lee WM. Acetaminophen and the U.S. Acute Liver Failure Study Group: lowering the risks of hepatic failure. *Hepatology* 2004; 40: 6-9. PubMed PMID: 15239078.
- (Editorial on burden of acetaminophen poisoning in the US, raising issue of limitation of the availability of acetaminophen as an over-the-counter agent).*
- Davern TJ 2nd. Acetaminophen hepatotoxicity. *Hepatology* 2004; 40: 1021-2; discussion 1022. PubMed PMID: 1538215.
- Parikh S, Dillon LC, Scharf SL. Hepatotoxicity possibly due to paracetamol with carbamazepine. *Intern Med J* 2004; 34: 441-2. PubMed PMID: 15271182.
- (80 year old woman with dementia given 4 g acetaminophen daily for 18 days developed liver injury [bilirubin 0.8 rising to 3.6 mg/dL, ALT 974 U/L, Alk P 161 U/L], resolving rapidly with NAC therapy).*
- Bygum A, Gregersen JW, Buus SK. Acetaminophen-induced toxic epidermal necrolysis in a child. *Pediatr Dermatol* 2004; 21: 236-8. PubMed PMID: 15165202.
- (6 year old boy developed toxic epidermal necrolysis [TEN] affecting 50-60% of body surface with a prolonged complicated course; later information was provided that he had taken acetaminophen daily for the 2 weeks before onset).*
- Shaoul R, Novikov J, Maor I, Jaffe M. Silent acetaminophen-induced hepatotoxicity in febrile children: does this entity exist? *Acta Paediatr* 2004; 93: 618-22. PubMed PMID: 15174783.
- (Prospective study of 107 children given acetaminophen during febrile illness; no correlation found between dose or plasma levels of acetaminophen with elevations in ALT or AST levels).*
- Russo MW, Galanko JA, Shrestha R, Fried MW, Watkins P. Liver transplantation for acute liver failure from drug induced liver injury in the United States. *Liver Transplant* 2004; 10: 1018-23. PubMed PMID: 15390328.
- (Analysis of 12 years of UNOS data found that 15% of liver transplants done for acute liver failure in the US were for drug induced liver disease, half attributed to acetaminophen, including 15 of 41 pediatric transplants).*
- Ayonrinde OT, Phelps GJ, Hurley JC, Ayonrinde OA. Paracetamol overdose and hepatotoxicity at a regional Australian hospital: a 4-year experience. *Intern Med J* 2005; 35: 655-60. PubMed PMID: 16248859.
- (Retrospective review of 192 cases of acute acetaminophen toxicity from a single Australian hospital found rising rates of overdose; 26 [13%] with hepatotoxicity, severe in 6 [3%], concurrent alcohol use did not correlate with severity of liver injury).*
- Björnsson E, Jerlstad P, Bergqvist A, Olsson R. Fulminant drug-induced hepatic failure leading to death or liver transplantation in Sweden. *Scand J Gastroenterol* 2005; 40: 1095-101. PubMed PMID: 16165719.
- (36 years of reporting to Swedish registry identified 103 cases of acute liver failure due to drugs; acetaminophen accounting for 14 [14%] and being the second most common cause, after halothane).*
- Dart RC, Green JL, Bogdan GM. The safety profile of sustained release paracetamol during therapeutic use and following overdose. *Drug Saf* 2005; 28: 1045-56. PubMed PMID: 16231956.
- (Literature search and analysis of poison center database indicated that sustained release forms of acetaminophen have similar safety and toxicity profile to standard acetaminophen, although nomogram may not be as accurate and levels may rise during monitoring).*
- Graham GG, Scott KF, Day RO. Tolerability of paracetamol. *Drug Saf* 2005; 28: 227-40. PubMed PMID: 15733027.
- (Review on tolerability of acetaminophen which concludes that "critical analysis indicates that most patients with alleged toxicity from therapeutic doses have taken overdoses").*

Wilkes JM, Clark LE, Herrera JL. Acetaminophen overdose in pregnancy. *South Med J* 2005; 98: 1118-22. PubMed PMID: 16351032.

(Review; acetaminophen can cross the placenta and cause hepatic injury in fetal liver; NAC crosses placenta as well).

Larson AM, Polson J, Fontana RJ, Davern TJ, Lalani E, Hynan LS, Reisch JS, et al., Acute Liver Failure Study Group. Acetaminophen-induced acute liver failure: results of a United States Multicenter, Prospective Study. *Hepatology* 2005; 42: 1364-72. PubMed PMID: 16317692.

(In a 6 year study at 22 US centers, 275 of 662 cases [42%] of acute liver failure were due to acetaminophen, accounting for 1/3rd of deaths; frequency increased over time from 28%-51%; 65% spontaneous survival, 8% transplanted, 27% died; about half were unintentional, with average total dose of 20 vs 25 g exposure; similar course and outcome to intentional overdose cases).

Björnsson E, Olsson R. Suspected drug-induced liver fatalities reported to the WHO database. *Dig Liver Dis* 2006; 38: 33-8. PubMed PMID: 16054882.

(In WHO database of fatal adverse drug reactions from 1968-2003, there were 4690 reports of drug induced liver fatality, acetaminophen being the most common cause [>300 cases: but 93% were reported from the US]).

Kozer E, Greenberg R, Zimmerman DR, Berkovitch M. Repeated suprathreshold doses of paracetamol in children - a literature review and suggested clinical approach. *Acta Paediatr* 2006; 95: 1165-71. PubMed PMID: 16982484.

(Review stressing the rarity of liver injury from acetaminophen in children, reported largely by hepatology referral centers, but rarely seen in cohort studies of acetaminophen overdoses; recommended using <75 mg/kg/day as a safe dose in children).

Kuffner EK, Temple AR, Cooper KM, Baggish JS, Parenti DL. Retrospective analysis of transient elevations in alanine aminotransferase during long-term treatment with acetaminophen in osteoarthritis clinical trials. *Curr Med Res Opin* 2006; 22: 2137-48. PubMed PMID: 17076974.

(Retrospective analysis of ALT results from 7 trials using acetaminophen [1950-4000 mg/day for 4-12 weeks, one for 12 months] for osteoarthritis, found no cases of hepatotoxicity or hepatic failure; 17% of participants had ALT elevation, but none >3 times ULN and high bilirubin; all resolved, some despite continuation of acetaminophen at previous dose).

James LP, Alonso EM, Hynan LS, Hinson JA, Davern TJ, Lee WM, Squires RH, Pediatric Acute Liver Failure Study Group. Detection of acetaminophen protein adducts in children with acute liver failure of indeterminate cause. *Pediatrics* 2006; 118: e676-e681. PubMed PMID: 16950959.

(N-acetylbenzquinoneimine metabolite of acetaminophen binds to cysteine residues of proteins and can be detected in serum with HPLC-EC; testing of 104 children with acute liver failure identified adducts in 90% of cases attributed to acetaminophen, but also in 9% of cases of other known cause and 12.5% of indeterminate cause; these cases having clinical features resembling acetaminophen hepatic injury).

Davern TJ 2nd, James LP, Hinson JA, Polson J, Larson AM, Fontana RJ, Lalani E, et al.; Acute Liver Failure Study Group. Measurement of serum acetaminophen-protein adducts in patients with acute liver failure. *Gastroenterology* 2006; 130: 687-94. PubMed PMID: 16530510.

(Acetaminophen-protein adducts detected in all 20 cases of acetaminophen induced acute liver failure in adults, but also in 19% [7/36] of cases of indeterminate cause; adduct levels fell in parallel with ALT, and long after acetaminophen was no longer detected by routine tests).

Mahadevan SB, McKiernan PJ, Davies P, Kelly DA. Paracetamol induced hepatotoxicity. *Arch Dis Child* 2006; 91: 598-603. PubMed PMID: 16547087.

(Analysis of 51 children with acetaminophen hepatotoxicity admitted to a single center from 1992-2002, 45 with single overdose, 6 with chronic use [<7 years]; 21 developed acute liver failure with encephalopathy; all with grade III encephalopathy either died [$n=5$] or underwent liver transplant [$n=6$]).

Moling O, Cairon E, Rimenti G, Rizza F, Pristerá, Mian P. Severe hepatotoxicity after therapeutic doses of acetaminophen. *Clin Ther* 2006; 28: 755-60. PubMed PMID: 16861097.

(45 year old man with HIV, HBV and HCV co-infection developed hepatic injury after taking 4 g of acetaminophen daily for 4 days for fever [bilirubin 2.3 mg/dL, ALT 5433 U/L, LDH 13,641 U/L, INR 2.1], recovering rapidly after N-acetylcysteine).

Ranganathan SS, Sathiadass MG, Sumanasena S, Fernandopulle M, Lamabadusuriya SP, Fernandopulle BM. Fulminant hepatic failure and paracetamol overuse with therapeutic intent in febrile children. *Indian J Pediatr* 2006; 73: 871-5. PubMed PMID: 17090896.

(All 25 children with acute liver failure presenting at a hospital in Colombo, Sri Lanka compared to only 33% of 33 hospitalized controls had consumed acetaminophen before presentation).

Brok J, Buckley N, Gluud C. Interventions for paracetamol(acetaminophen) overdose. *Cochrane Database Syst Rev* 2006;(2): CD003328. PubMed PMID: 16625578.

(Systematic review of literature on interventions for acetaminophen overdose, supports use of N-acetylcysteine; activated charcoal delays absorption of acetaminophen, but its efficacy in decreasing injury is unclear).

Watkins PB, Kaplowitz N, Slattery JT, Colonese CR, Colucci SV, Stewart PW, Harris SC. Aminotransferase elevations in healthy adults receiving 4 grams of acetaminophen daily: a randomized controlled trial. *JAMA*. 2006; 296: 87-93. PubMed PMID: 16820551.

(Randomized controlled trial of acetaminophen [4 g daily for 14 days] in combination with various other analgesics versus placebo in 134 healthy controls found elevations in ALT levels to be common with acetaminophen and not affected by the combination with other agents: ALT levels rose above 3 times ULN in 39%, >5 times in 25% and >8 times in 8%; no patient had symptoms or became jaundiced, and elevations resolved rapidly with discontinuation: Case #1).

Yuan Y, Thabane M, Thabane L, Hunt RH. Acetaminophen and aminotransferase elevations. *JAMA* 2006; 296: 2798; author reply 2798-9. PubMed PMID: 17179451.

(Letter in response to Watkins et al. [2006] raising statistical and design issues without new information).

Khashab M, Tector AJ, Kwo PY. Epidemiology of acute liver failure. *Curr Gastroenterol Rep* 2007; 9: 66-73. PubMed PMID: 17335680.

(Review of frequency and major causes of acute liver failure).

Brune K, Nitschmann S. [Liver toxicity of paracetamol] *Internist(Berl)* 2007; 48: 1036-8. German. PubMed PMID: 1771253.

Dart RC, Bailey E. Does therapeutic use of acetaminophen cause acute liver failure? *Pharmacotherapy* 2007; 27: 1219-30. PubMed PMID: 17723075.

(Analysis of literature on safety of high but therapeutic doses of acetaminophen: among 30,865 patients followed prospectively, no case of acute liver failure was identified and only 0.4% of patients had ALT levels above the ULN [often similar to rate in controls]; among 9,337 patients in retrospective studies, 1.0% had ALT elevations and 0.07% had acute liver failure, some of whom may have taken higher than prescribed doses).

Dart RC, Rumack BH. Patient-tailored acetylcysteine administration. *Ann Emerg Med* 2007; 50: 280-1. 17418449. PubMed PMID: 17418449.

(Editorial discussing difficulties of shortening the course of N-acetylcysteine therapy based upon response).

- Escorsell A, Mas A, de la Mata M; Spanish Group for the Study of Acute Liver Failure. Acute liver failure in Spain: analysis of 267 cases. *Liver Transpl* 2007; 13: 1389-95. PubMed PMID: 17370334.
- (In Spain, acetaminophen hepatotoxicity is uncommon, accounting for only 6 of 267 cases [2%] of acute liver failure identified at 17 referral hospitals between 1992 and 2000; other causes included HBV in 29%, other drugs in 20%).*
- Heard K, Green JL, Bailey JE, Bogdan GM, Dart RC. A randomized trial to determine the change in alanine aminotransferase during 10 days of paracetamol (acetaminophen) administration in subjects who consume moderate amounts of alcohol. *Aliment Pharmacol Ther* 2007; 26: 283-90. PubMed PMID: 17593074.
- (Among 156 patients randomized to acetaminophen [4 g/day] or placebo for 10 days with liver tests at 0, 4 and 11 days, ALT elevations occurred in ~20% of acetaminophen treated patients; mostly <3 times ULN, only 1 >3 times ULN. On rechallenge, all redeveloped ALT elevations; no follow up).*
- Kc S. Acute liver failure caused by hepatitis E virus and paracetamol. *JNMA J Nepal Med Assoc* 2007; 46: 74-6. PubMed PMID: 18094741.
- (45 year old man developed fatigue and body aches and took 4 g of acetaminophen for 2 days developing jaundice, stupor and coma [bilirubin 11.3 mg/dL, ALT 580 U/L, Alk P 406 U/L, IgM anti-HEV positive]; given N-acetylcysteine and recovered; authors raise issue of whether acetaminophen worsened course of acute hepatitis E).*
- Olosová, Lásová, Zaoral T, Bakhtary A. [The use of paracetamol in children--not just a drug but also a poison] *Cas Lek Cesk* 2007; 146: 401-5; discussion 405-6. Czech. PubMed PMID: 1749125.
- Satirapoj B, Lohachit P, Ruamvang T. Therapeutic dose of acetaminophen with fatal hepatic necrosis and acute renal failure. *J Med Assoc Thai* 2007; 90: 1244-7. PubMed PMID: 17624227.
- (33 year old woman developed fatal acute liver failure while on therapeutic doses of acetaminophen [bilirubin 12.5 mg/dL, ALT 4640 U/L, creatinine 5.2 mg/dL]).*
- Schmidt LE, Larsen FS. MELD score as a predictor of liver failure and death in patients with acetaminophen-induced liver injury. *Hepatology* 2007; 45: 789-96. PubMed PMID: 17326205.
- (MELD scores were reasonably predictive of hepatotoxicity and acute liver failure from acetaminophen, but not of survival).*
- Thomas MB, Moran N, Smart K, Crean S. Paracetamol overdose as a result of dental pain requiring medical treatment - two case reports. *Br Dent J* 2007; 203: 25-8. PubMed PMID: 17632482.
- (Woman and man, both 20 years old, developed signs of overdose after taking excessive doses of acetaminophen [250-428 mg/kg] because of severe tooth pain; liver injury was mild and rapidly reversed).*
- Tokatli A, Kalkanoglu-Sivri HS, Yüce A, Coskun T. Acetaminophen-induced hepatotoxicity in a glutathione synthetase-deficient patient. *Turk J Pediatr* 2007; 49: 75-6. PubMed PMID: 17479648.
- (Abstract: Nine month old girl with oxoprolinuria presented with metabolic acidosis but normal ALT levels after acetaminophen; probably unrelated).*
- Larson AM. Acetaminophen hepatotoxicity. *Clin Liver Dis* 2007; 11: 525-48. PubMed PMID: 17723918.
- (Review of mechanisms and management of acetaminophen hepatotoxicity).*
- Wei G, Bergquist A, Broomé, Lindgren S, Wallerstedt S, Almer S, Sangfelt P, et al. Acute liver failure in Sweden: etiology and outcome. *J Intern Med* 2007; 262: 393-401. PubMed PMID: 17697161.
- (Retrospective study of 279 patients presenting with acute liver failure during 10 years at 10 medical centers in Sweden; 118 [48%] were due to acetaminophen with spontaneous survival in 83%, transplantation in 5%, and death in 12%).*

- Kuffner EK, Green JL, Bogdan GM, Knox PC, Palmer RB, Heard K, Slattery JT, et al. The effect of acetaminophen (four grams a day for three consecutive days) on hepatic tests in alcoholic patients - a multicenter randomized study. *BMC Medicine* 2007; 5: 1-9. PubMed PMID: 17537264.
- (443 subjects entering alcohol rehab program were randomized to acetaminophen [4 g/day] or placebo for 3 days; ALT levels rose slightly but similarly in acetaminophen and placebo recipients).*
- Hawkins LC, Edwards JN, Dargan PI. Impact of restricting paracetamol pack sizes on paracetamol poisoning in the United Kingdom: a review of the literature. *Drug Saf* 2007; 30: 465-79. PubMed PMID: 17536874.
- (1998 legislation in UK restricted acetaminophen packaging and sales; 17 publications reviewed studies of effects of this legislation, many of which had conflicting results).*
- Amar PJ, Schiff ER. Acetaminophen safety and hepatotoxicity--where do we go from here? *Expert Opin Drug Saf* 2007; 6: 341-55. PubMed PMID: 17688378.
- (Review with annotated references on acetaminophen hepatotoxicity).*
- Spiller HA, Sawyer TS. Impact of activated charcoal after acute acetaminophen overdoses treated with N-acetylcysteine. *J Emerg Med* 2007; 33: 141-4. PubMed PMID: 17692765.
- (Retrospective analysis of reports of acetaminophen overdose; deaths were less common in those receiving both N-acetylcysteine [NAC] and activated charcoal [0.5%] compared to NAC alone [0.8%], but comparisons were not controlled for timing or severity).*
- Walls L, Baker CF, Sarkar S. Acetaminophen-induced hepatic failure with encephalopathy in a newborn. *J Perinatol* 2007; 27: 133-5. PubMed PMID: 17262050.
- (4 day old infant admitted with renal and hepatic failure [bilirubin 9 mg/dl, ALT 978 U/L, protime 52 sec] after being given acetaminophen by parents for 3 days for circumcision pain; recovered with support and N-acetylcysteine infusions).*
- Ali FM, Boyer EW, Bird SB. Estimated risk of hepatotoxicity after an acute acetaminophen overdose in alcoholics. *Alcohol* 2008; 42: 213-8. PubMed PMID: 18358677.
- (Calculated risk of hepatotoxicity after acetaminophen overdose using regression model arguing for a lower threshold for toxicity in abstinent alcoholics).*
- Allegaert K, Rayyan M, De Rijdt T, Van Beek F, Naulaers G. Hepatic tolerance of repeated intravenous paracetamol administration in neonates. *Paediatr Anaesth* 2008; 18: 388-92. PubMed PMID: 18384338.
- (Intravenous acetaminophen is used in neonates for treatment of pain; in a retrospective analysis of liver tests before, during and after 1-4 days; among 2360 administrations in 189 children, no significant increases in ALT or AST found).*
- Carey EJ, Vargas HE, Douglas DD, Balan V, Byrne TJ, Harrison ME, Rakela J. Inpatient admissions for drug-induced liver injury: results from a single center. *Dig Dis Sci* 2008; 53: 1977-82. PubMed PMID: 18392678.
- (Analysis of 40 cases of drug induced liver disease admitted to a single referral center over 8 year period; 27 were acetaminophen related, 1/3rd of which were unintentional [bilirubin 1.9-11.7 mg/dL, ALT 230-4422 U/L, Alk P 99-203 U/L], 6 fatal).*
- Grieco A, Miele L, Forgione A, Ragazzoni E, Vecchio FM, Gasbarrini G. Mild hepatitis at recommended doses of acetaminophen in patients with evidence of constitutionally enhanced cytochrome P450 system activity. *J Clin Pharm Ther* 2008; 33: 315-20. PubMed PMID: 18452419.
- (37 year old woman and 57 year old man on 2 and 4 g of acetaminophen daily had ALT elevations [200 and 281 U/L] without symptoms or jaundice, resolving with stopping therapy; liver biopsies showed mild portal*

inflammation and minimal focal necrosis; antipyrine clearance testing suggested these patients had increased metabolism of acetaminophen through P450 system).

Hamwi I, Picksak G, Stichtenoth DO. [Accidental acetaminophen overdose] *Med Monatsschr Pharm* 2008; 31: 224-5. German. PubMed PMID: 18661913.

(Abstract: stresses importance of high doses of acetaminophen in causing unintentional hepatotoxicity).

Pearce B, Grant IS. Acute liver failure following therapeutic paracetamol administration in patients with muscular dystrophies. *Anaesthesia* 2008; 63: 89-91. PubMed PMID: 18086077.

(Two men, ages 20 and 42 years, with muscular dystrophy in ICU for respiratory failure were given acetaminophen [4 g daily] and developed acute liver failure within 3 days [bilirubin 19.4 and 7.3 mg/dL, ALT 2267 and 3850 U/L, prolonged INR]; both recovered; authors hypothesize that muscular dystrophy may be a risk factor).

Saviuc P, Danel V. [Acute acetaminophen overdose] *Rev Prat* 2008; 58: 861-5. French. PubMed PMID: 18630824.

(Review article on management of acetaminophen overdose).

Waring WS, Robinson OD, Stephen AF, Dow MA, Pettie JM. Does the patient history predict hepatotoxicity after acute paracetamol overdose? *QJM* 2008; 101: 121-5. PubMed PMID: 18180256.

(Prospective study of 987 patients with acetaminophen overdose, found patient history of amount taken was a partially reliable marker of subsequent liver injury; if ingestion was >12 g, 32% had hepatotoxicity; if <12 g, 3.2%).

Waring WS, Robinson OD, Stephen AF, Dow MA, Pettie JM. Serum urea concentration and the risk of hepatotoxicity after paracetamol overdose? *QJM* 2008; 101: 359-363. PubMed PMID: 18334496.

(Analysis of 1191 patients with acetaminophen overdose; baseline urea values did not predict development of hepatotoxicity, although urea values tended to be low in those admitting to chronic alcohol use).

James LP, Capparelli EV, Simpson PM, Letzig L, Roberts D, Hinson JA, Kearns GL, et al.; Network of Pediatric Pharmacology Research Units, National Institutes of Child Health and Human Development. Acetaminophen-associated hepatic injury: evaluation of acetaminophen protein adducts in children and adolescents with acetaminophen overdose. *Clin Pharmacol Ther* 2008; 84: 684-90. PubMed PMID: 18923390.

(Acetaminophen adducts were measured in 157 children presenting with overdose; peak adduct levels correlated with AST and ALT levels, time after overdose, and nomogram risk).

Bartels S, Sivilotti M, Crosby D, Richard J. Are recommended doses of acetaminophen hepatotoxic for recently abstinent alcoholics? A randomized trial. *Clin Toxicol* 2008; 46: 243-9. PubMed PMID: 18344107.

(Randomized controlled trial of acetaminophen [4 g/day for 4 days] vs placebo in 52 patients in an alcohol withdrawal program, found no differences in ALT or AST levels over 5 days).

Polson J, Wians FH Jr, Orsulak P, Fuller D, Murray NG, Koff JM, Khan AI, et al.; Acute Liver Failure Study Group. False positive acetaminophen concentrations in patients with liver injury. *Clin Chim Acta* 2008; 391: 24-30. PubMed PMID: 18279672.

(Assessment of 6 different assays for plasma acetaminophen levels found frequent, but low level false positive results using colorimetric, but not immunoassays; probably due to bilirubin).

Murray KF, Hadzic N, Wirth S, Bassett M, Kelly D. Drug-related hepatotoxicity and acute liver failure. *J Pediatr Gastroenterol Nutr* 2008; 47: 395-405. PubMed PMID: 18852631.

(Review of drug induced acute liver failure in children; among 348 cases in Pediatric ALF Study, 14% were due to acetaminophen [94% spontaneous survival without transplant] and 5% to other medications [only 36% spontaneous survival]).

Smith SW, Howland MA, Hoffman RS, Nelson LS. Acetaminophen overdose with altered acetaminophen pharmacokinetics and hepatotoxicity associated with premature cessation of intravenous N-acetylcysteine therapy. *Ann Pharmacother* 2008; 42: 1333-9. PubMed PMID: 18628444.

(78 year old man took 48 g of acetaminophen and was started on iv N-acetylcysteine [NAC] within 5 hours; serum acetaminophen levels fell, but then rose 12-24 hours after the 21-hour NAC infusion was stopped with subsequent marked rise in ALT [5621 U/L]; NAC continued for 10 more days and patient survived).

Myers RP, Shaheen AA, Li B, Dean S, Quan H. Impact of liver disease, alcohol abuse, and unintentional ingestions on the outcomes of acetaminophen overdose. *Clin Gastroenterol Hepatol* 2008; 6: 918-25 PubMed PMID: 18486561.

(Among 1543 patients with acetaminophen overdose seen between 1995-2004 followed in a Canadian health care region, 4.5% developed hepatotoxicity; in multivariate analysis risk factors for liver injury were underlying liver disease, unintentional overdose and alcohol abuse).

Doyon S, Klein-Schwartz W. Hepatotoxicity despite early administration of intravenous N-acetylcysteine for acute acetaminophen overdose. *Acad Emerg Med* 2009; 16: 34-9. PubMed PMID: 19007345.

(Retrospective analysis of 77 patients with acetaminophen overdose receiving 21 hours of iv N-acetylcysteine starting 1-8 hours after ingestion, 7 patients [9%] had acetaminophen detectable in serum or elevated ALT levels at end of therapy, one of whom died and one underwent liver transplant for acute liver failure, suggesting that therapy should be prolonged for some patients).

Majlesi N, Olsen A, Krishnan GP, Olsen D, Nelson L. Hepatotoxicity despite early administration of intravenous N-acetylcysteine for acute acetaminophen overdose. *Acad Emerg Med* 2009; 16: 574; author reply 575. PubMed PMID: 19426297.

(Letter in response to Doyon [2009] raising issue of unusual finding of late rise in levels of acetaminophen and the possibility of re-ingestion).

Cooper SC, Aldridge RC, Shah T, Webb K, Nightingale P, Paris S, Gunson BK, et al. Outcomes of liver transplantation for paracetamol (acetaminophen)-induced hepatic failure. *Liver Transpl* 2009; 15: 1351-7. PubMed PMID: 19790165.

(Among 858 patients with acute liver injury from acetaminophen seen in a UK center between 1989 and 2007, 60 [7%] underwent liver transplantation of whom 73% survived to discharge and 58% survived long term, these rates being lower than for transplantation for chronic liver disease or other forms of acute liver failure).

Suzuki A, Yuen N, Walsh J, Papay J, Hunt CM, Diehl AM. Co-medications that modulate liver injury and repair influence clinical outcome of acetaminophen-associated liver injury. *Clin Gastroenterol Hepatol* 2009; 7: 882-8. PubMed PMID: 19362607.

(Analysis of acetaminophen-induced liver injury from the FDA Adverse Event Reporting System comparing fatal [n=2512] to non-fatal [n=3874] cases found higher rates of alcohol use, but lower rates of statin and nonsteroid antiinflammatory drug use among fatal cases).

Myers RP, Shaheen AA. Hepatitis C, alcohol abuse, and unintentional overdoses are risk factors for acetaminophen-related hepatotoxicity. *Hepatology* 2009; 49: 1399-400. PubMed PMID: 19330871.

(Analysis of database of 42,718 hospitalizations for acetaminophen overdose, of which 1.7% had hepatitis C who had a higher rate of hepatotoxicity [16.7% vs 4.5%] than noninfected overdose patients).

- Kubic A, Burda AM, Bockewitz E, Wahl M. Hepatotoxicity in an infant following suprathreshold dosing of acetaminophen for twenty-four hours. *Semin Diagn Pathol* 2009; 26: 7-9. PubMed PMID: 19292023.
- (7 month old boy was given higher than recommended dose of acetaminophen [234 mg/kg/24 hours: 1.8 g] and presented with vomiting [bilirubin 0.3 mg/dL, ALT 907 U/L, AST 1339 U/L, Alk P 205 U/L], responding to iv N-acetylcysteine for 37 hours with rapid improvement and had normal enzyme levels 10 days later).*
- Betten DP, Burner EE, Thomas SC, Tomaszewski C, Clark RF. A retrospective evaluation of shortened-duration oral N-acetylcysteine for the treatment of acetaminophen poisoning. *J Med Toxicol* 2009; 5: 183-90. PubMed PMID: 19876849.
- (Retrospective analysis of outcome of shortened courses of oral N-acetylcysteine for acetaminophen overdose based upon analysis of 1932 cases reported to the California Poison Control System between 1999-2003, follow up finding no evidence of deaths from liver failure in those with early discontinuation).*
- Miller AL. Liver damage from chronic acetaminophen dosing is dangerous, but not the only risk. *Altern Med Rev* 2009; 14: 322-3. PubMed PMID: 20030459.
- (Editorial discussing role of acetaminophen in causing ALT elevations, but also affecting immune system and possibly causing autism).*
- Jickling G, Heino A, Ahmed SN. Acetaminophen toxicity with concomitant use of carbamazepine. *Epileptic Disord* 2009; 11: 329-32. PubMed PMID: 19995690.
- (34 year old man on long term carbamazepine developed abdominal pain 2 weeks after starting 2.0-2.5 g of acetaminophen daily [bilirubin not given, ALT 9101 U/L], enzymes falling to normal within 2 weeks with N-acetylcysteine and prednisone therapy).*
- Yarema MC, Johnson DW, Berlin RJ, Sivilotti ML, Nettel-Aguirre A, Brant RF, Spyker DA, et al. Comparison of the 20-hour intravenous and 72-hour oral acetylcysteine protocols for the treatment of acute acetaminophen poisoning. *Ann Emerg Med* 2009; 54: 606-14. PubMed PMID: 19556028.
- (Retrospective comparison of 20 hour intravenous vs 72 hour oral regimen of N-acetylcysteine [NAC] for acetaminophen overdose in 4048 patients, found rates of hepatotoxicity [AST or ALT >1000 U/L] of 13.9% vs 15.8%. 1 patient underwent transplant with iv regimen [20 hours] and 3 patients died with oral regimen [19-24 hours]; iv regimen may have been superior for early and oral for late cases; anaphylactic reaction to iv NAC in 7.1%).*
- Gupta AK, Su MK, Greller HA, Lee DC, Chan GM. IV versus oral N-acetylcysteine. *Ann Emerg Med* 2009; 54: 857-8; author reply 858-9. PubMed PMID: 19942075.
- (Letter in response to Yarema [2009] questioning whether AST elevations should be used as an endpoint in assessing efficacy of N-acetylcysteine regimens).*
- Bond GR. Is the oral acetylcysteine protocol the best treatment for late-presenting acetaminophen poisoning? *Ann Emerg Med* 2009; 54: 615-7. PubMed PMID: 19695740.
- (Editorial regarding Yarema [2009] discussing the shortcomings of data on the optimal regimen of N-acetylcysteine therapy for acetaminophen overdose).*
- Traynor K. FDA's acetaminophen meeting sparks confusion, uncertainty. *Am J Health Syst Pharm* 2009; 66: 1422, 1425-6. PubMed PMID: 19666995.
- (News article on 2009 FDA meeting on the safety of acetaminophen and possible steps to decrease the amount in prescription and nonprescription products).*
- Kuehn BM. FDA focuses on drugs and liver damage: labeling and other changes for acetaminophen. *JAMA* 2009; 302: 369-71. PubMed PMID: 19622807.

(News article on FDA initiative to reduce acetaminophen associated liver injury, reports of which increased from 89 in 1995 to 404 in 2005).

Acetaminophen safety - deja vu. *Med Lett Drugs Ther* 2009; 51 (1316): 53-4, 56. PubMed PMID: 19590488.

(Reprint of a brief overview of acetaminophen effectiveness and safety from 2002).

Levi N, Bastuji-Garin S, Mockenhaupt M, Roujeau JC, Flahault A, Kelly JP, Martin E, et al. Medications as risk factors of Stevens-Johnson syndrome and toxic epidermal necrolysis in children: a pooled analysis. *Pediatrics* 2009; 123: e297-304. PubMed PMID: 19153164.

(Among 80 cases of SJS/TEN in children [<15 years] identified in 2 large prospective databases from Europe, the most commonly implicated drugs were antibiotics, antiepileptics and NSAIDs, but 24 children [37%] were exposed to acetaminophen in the week before onset compared to 7% [11/216] controls).

Trujillo C, Gago C, Ramos S. Stevens-Johnson syndrome after acetaminophen ingestion, confirmed by challenge test in an eleven-year-old patient. *Allergol Immunopathol (Madr)* 2010; 38: 99-100. PubMed PMID: 19875224.

(11 year old boy developed rash with target-like bullae followed by SJS 3 days after starting acetaminophen for a cold, having previously tolerated it; after recovery he redeveloped skin rash within 48 hours of re-exposure [no liver test results provided]).

Duh MS, Vekeman F, Korves C, Lefebvre P, Dial E, Latremouille-Viau D, Wei RS, et al. Risk of hepatotoxicity-related hospitalizations among patients treated with opioid/acetaminophen combination prescription pain medications. *Pain Med* 2010; 11: 1718-25. PubMed PMID: 21044262.

(Retrospective cohort study examining insurance claims; found no increased risk of hospitalization due to opioid/acetaminophen combination).

Green TJ, Sivilotti ML, Langmann C, Yarema M, Juurlink D, Burns MJ, Johnson DW. When do the aminotransferases rise after acute acetaminophen overdose? *Clin Toxicol (Phila)* 2010; 48: 787-92. PubMed PMID: 20969501.

(Analysis of early changes in ALT levels in 94 cases of acetaminophen overdose with liver injury from a Canadian registry showed that ALT levels were usually elevated within 24 hours of ingestion and rose above 1,000 U/L by 24 to 48 hours).

Jepsen P, Schmidt LE, Larsen FS, Vilstrup H. Long-term prognosis for transplant-free survivors of paracetamol-induced acute liver failure. *Aliment Pharmacol Ther* 2010; 32: 894-900. PubMed PMID: 20735774.

(Among 641 patients who survived after acetaminophen overdose with liver injury in Denmark, rates of long term survival were similar in those who had acute liver failure compared to those with milder injury; none died of cirrhosis or liver failure, suicide was frequent).

Lee WM. The case for limiting acetaminophen-related deaths: smaller doses and unbundling the opioid-acetaminophen compounds. *Clin Pharmacol Ther* 2010; 88: 289-92. PubMed PMID: 20725075.

(Since 2000, acetaminophen has accounted for 38-53% of cases of acute liver failure in the United States and half of cases were unintentional overdose; discussion of regulatory approaches to decreasing this problem).

Heard KJ, Green JL, Dart RC. Serum alanine aminotransferase elevation during 10 days of acetaminophen use in nondrinkers. *Pharmacotherapy* 2010; 30: 818-22. PubMed PMID: 20653358.

(Among 24 healthy volunteers given acetaminophen [4 g daily] for 10 days, 58% developed at least one ALT elevation, but all were mild [peak ~140 U/L], transient, and not associated with symptoms or bilirubin elevations).

- Devarbhavi H, Dierkhising R, Kremers WK, Sandeep MS, Karanth D, Adarsh CK. Single-center experience with drug-induced liver injury from India: causes, outcome, prognosis, and predictors of mortality. *Am J Gastroenterol* 2010; 105: 2396-404. PubMed PMID: 20648003.
- (Among 313 cases of drug induced liver injury seen over a 12 year period at a large hospital in Bangalore, India, <1% were attributed to acetaminophen).*
- Bernal W, Auzinger G, Dhawan A, Wendon J. Acute liver failure. *Lancet* 2010; 376(9736): 190-201. PubMed PMID: 20638564.
- (Review describes acute liver failure caused by acetaminophen as "hyperacute", with rapid onset of encephalopathy, severe coagulopathy, mild to moderate jaundice and high rate of survival without transplantation; accounting for 36-57% of cases in UK, US, Australia and Sweden, but only 2% in Spain and <1% in India, Pakistan and the Sudan).*
- Albertson TE, Walker VM Jr, Stebbins MR, Ashton EW, Owen KP, Sutter ME. A population study of the frequency of high-dose acetaminophen prescribing and dispensing. *Ann Pharmacother* 2010; 44: 1191-5. PubMed PMID: 20551297.
- (Analysis of Medicaid pharmacy claims over a 1 year period in California found 5.9% of beneficiaries were potentially exposed to >4 g and some >16 g of acetaminophen daily).*
- Livshits Z, Hoffman RS. Comment: a population study of the frequency of high-dose acetaminophen prescribing and dispensing. *Ann Pharmacother* 2010; 44: 1856. PubMed PMID: 20959504.
- (Letter in response to Albertson [2010] raising issue of whether liver injury arises as a result of standard [up to 4 g/day] or only with higher doses).*
- Dart RC, Green JL, Kuffner EK, Heard K, Sproule B, Brands B. The effects of paracetamol (acetaminophen) on hepatic tests in patients who chronically abuse alcohol - a randomized study. *Aliment Pharmacol Ther* 2010; 32: 478-86. PubMed PMID: 20491750.
- (Among 142 newly abstinent, alcoholic subjects given acetaminophen [4 g daily] or placebo for 5 days, mean ALT levels rose minimally in both acetaminophen [48 to 62 U/L] and placebo [47 to 49 U/L] groups, while bilirubin levels fell and INR values were stable).*
- Michna E, Duh MS, Korves C, Dahl JL. Removal of opioid/acetaminophen combination prescription pain medications: assessing the evidence for hepatotoxicity and consequences of removal of these medications. *Pain Med* 2010; 11: 369-78. PubMed PMID: 20447306.
- (Review of the literature on the role of opioid/acetaminophen combinations in causing hepatotoxicity concluded "there is no reliable information from which we can draw conclusions about the absolute or relative risk of these medications", which led authors to argue against regulatory restriction of this combination).*
- Hendrickson RG, McKeown NJ, West PL, Burke CR. Bactrian ("double hump") acetaminophen pharmacokinetics: a case series and review of the literature. *J Med Toxicol* 2010; 6: 337-44. PubMed PMID: 20446076.
- (Three patients, 2 women and one boy, ages 38, 25 and 16 years, were seen soon after large acetaminophen overdoses [65, 26 and 100 g] and found to have a second rise in serum acetaminophen levels at 37-42 hours with subsequent liver injury [peak ALT 2351, 2236 and 10,832 U/L at 97, 109 and 91 hours], all received N-acetylcysteine and all survived).*
- Karvellas CJ, Safinia N, Auzinger G, Heaton N, Muiesan P, O'Grady J, Wendon J, et al. Medical and psychiatric outcomes for patients transplanted for acetaminophen-induced acute liver failure: a case-control study. *Liver Int* 2010; 30: 826-33. PubMed PMID: 20408947.

- (Outcome after liver transplantation was similar for patients with acetaminophen- vs non-acetaminophen induced acute liver failure, but 2 of 36 acetaminophen cases subsequently reattempted suicide, one successfully).*
- Barritt AS 4th, Lee J, Hayashi PH. Detective work in drug-induced liver injury: sometimes it is all about interviewing the right witness. *Clin Gastroenterol Hepatol* 2010; 8: 635-7. PubMed PMID: 20363371.
- (4 patients with drug induced liver injury were misdiagnosed because the drug was not mentioned or acknowledged in the initial medical history; alfuzosin, acetaminophen and, in two, amoxicillin/clavulanate).*
- Zyoud SH, Awang R, Sulaiman SA, Al-Jabi SW. Association between gastrointestinal manifestations following acetaminophen poisoning and outcome in 291 acetaminophen poisoning patients. *Pharmacoepidemiol Drug Saf* 2010; 19: 511-7. PubMed PMID: 20333776.
- (Among 291 patients with acetaminophen overdose seen over a 5 year period, 77% developed gastrointestinal manifestations [nausea, pain, diarrhea] which were associated with higher doses, longer latency and more renal and hepatic complications, but no patient died).*
- Gregory B, Larson AM, Reisch J, Lee WM; Acute Liver Failure Study Group. Acetaminophen dose does not predict outcome in acetaminophen-induced acute liver failure. *J Investig Med* 2010; 58: 707-10. PubMed PMID: 20305573.
- (Analysis of estimated dose of acetaminophen with risk of acute liver failure after intentional overdose found that the dose estimates did not correlate well with severity or outcome).*
- Graham GG, Day RO, Graudins A, Mohamudally A. FDA proposals to limit the hepatotoxicity of paracetamol (acetaminophen): are they reasonable? *Inflammopharmacology* 2010; 18: 47-55. PubMed PMID: 20213329.
- (Discussion of the options proposed by the FDA for limiting the hepatotoxicity of acetaminophen).*
- Bateman DN, Dear J. Medicine, poison, and mystic potion: a personal perspective on paracetamol Louis Roche lecture, Stockholm, 2009. *Clin Toxicol (Phila)* 2010; 48: 97-103. PubMed PMID: 20199128.
- (Review of the history of diagnosis and management of acetaminophen overdose).*
- Winnike JH, Li Z, Wright FA, Macdonald JM, O'Connell TM, Watkins PB. Use of pharmaco-metabonomics for early prediction of acetaminophen-induced hepatotoxicity in humans. *Clin Pharmacol Ther* 2010; 88: 45-51. PubMed PMID: 20182423.
- (Analysis of urinary metabonomic profiles in healthy volunteers given acetaminophen [4 g daily] for 7 days [Watkins 2006] identified N-acetyl paraquinone imine [NAPQ] metabolites that predicted who would develop liver injury before the actual onset).*
- Lavonas EJ, Reynolds KM, Dart RC. Therapeutic acetaminophen is not associated with liver injury in children: a systematic review. *Pediatrics* 2010; 126: e1430-44. PubMed PMID: 21098156.
- (Systematic review of literature on acetaminophen hepatotoxicity in children receiving therapeutic doses [<75 mg/kg/day]; no instance of clinically apparent liver injury was reported in defined population studies; but 22 published case reports were identified, although on re-review only 9 were considered probable).*
- Shivbalan S, Sathiyasekeran M, Thomas K. Therapeutic misadventure with paracetamol in children. *Indian J Pharmacol* 2010; 42: 412-5. PubMed PMID: 21189918.
- (Six infants, ages 6 weeks to 3 years, were given excessive doses of acetaminophen [100-367 mg/k/day] and were treated with N-acetylcysteine, 3 had ALT elevations [1026, 529 and 569 U/L], 5 recovered and 1 [who also had dengue fever] died of multiorgan failure).*
- Claridge LC, Eksteen B, Smith A, Shah T, Holt AP. Acute liver failure after administration of paracetamol at the maximum recommended daily dose in adults. *BMJ* 2010; 341: c6764. PubMed PMID: 21127120.

(43 year old man with Crohn disease given acetaminophen [4 g daily] for 4 days developed acute liver failure [AST 12,769 U/L, INR 9.1] and died 12 days later despite prompt therapy with N-acetylcysteine [NAC]; 32 year old woman with alcoholism given acetaminophen [4 g daily] for 3 days developed acute liver failure [AST 7116 U/L, INR 3.2] and recovered after NAC therapy).

Claridge LC, Eksteen B, Smith A, Shah T, Holt AP. [Acute liver failure after administration of paracetamol at the maximum recommended daily dose in adults]. *Praxis (Bern 1994)* 2011; 100: 923-6. German. PubMed PMID: 21792808.

(German language version of Claridge [2010]).

Haga C, Muan B, Cheung M, Lyngra M, Strømsæther CE, Lutro O, Andrew E. [Paracetamol poisonings after the lifting of the place of sale restriction]. *Tidsskr Nor Laegeforen* 2011; 131: 2115-8. Norwegian. PubMed PMID: 22048206.

(Analysis of a national poison registry in Norway between 2001 and 2006 found no increase in hospitalizations for acetaminophen poisonings despite national restrictions on its purchase being lifted in 2003).

Starkey Lewis PJ, Dear J, Platt V, Simpson KJ, Craig DG, Antoine DJ, French NS, et al. Circulating microRNAs as potential markers of human drug-induced liver injury. *Hepatology* 2011; 54: 1767-76. PubMed PMID: 22045675.

(Liver associated micro-RNA levels [miR-122 and miR-192] were elevated in cases of acute liver injury due to acetaminophen and other causes compared to controls; miR-122 levels correlated best with ALT elevations).

Mort JR, Shiyabola OO, Ndehi LN, Xu Y, Stacy JN. Opioid-paracetamol prescription patterns and liver dysfunction: a retrospective cohort study in a population served by a US health benefits organization. *Drug Saf* 2011; 34: 1079-88. PubMed PMID: 21981435.

(Analysis of data from 4.8 million health beneficiaries found 5.3 million prescriptions for opioid-acetaminophen combinations, 19% of which exceeded the recommended maximal daily acetaminophen dose of 4 g).

Palmer KA, Shane R. Care needed with i.v. acetaminophen. *Am J Health Syst Pharm* 2011; 68: 1775-6. PubMed PMID: 21930633.

(Letter on the potential of making errors in dosing of intravenous acetaminophen and the need for care).

Chomchai S, Chomchai C, Anusornsuwan T. Acetaminophen psi parameter: a useful tool to quantify hepatotoxicity risk in acute acetaminophen overdose. *Clin Toxicol (Phila)* 2011; 49: 664-7. PubMed PMID: 21819286.

(Analysis of whether the psi parameter [acetaminophen level 4 hours after ingestion and time to start of N-acetylcysteine] was predictive of hepatotoxicity).

Li C, Martin BC. Trends in emergency department visits attributable to acetaminophen overdoses in the United States: 1993-2007. *Pharmacoepidemiol Drug Saf* 2011; 20: 810-8. PubMed PMID: 21796717.

(Estimated rates of emergency department visits due to acetaminophen overdose decreased from 21 to 15 per 100,000 person-years between 1993 and 2007 and accounted for 44-56,000 visits yearly).

Sabaté M, Ibáñez L, Pérez E, Vidal X, Buti M, Xiol X, Mas A, et al. Paracetamol in therapeutic dosages and acute liver injury: causality assessment in a prospective case series. *BMC Gastroenterol* 2011; 11: 80. PubMed PMID: 21762481.

(In a population-based study conducted in Spain between 1993 and 2000, 32 of 126 cases of acute liver injury were identified in patients taking "therapeutic" doses of acetaminophen, but only 4 cases were considered probably and 3 possibly due to acetaminophen using the RUCAM scoring system, yielding an population based incidence of 10 per million acetaminophen users).

Clement C, Scala-Bertola J, Javot L, Royer-Morrot MJ, Gillet P, Trechot P, Petitpain N, et al. Misuse of acetaminophen in the management of dental pain. *Pharmacoepidemiol Drug Saf* 2011; 20: 996-1000. PubMed PMID: 21726014.

(During a 9 month period, 13 cases of unintentional acetaminophen overdose [71-842 mg/kg/24 hr] in dental patients were reported to a French Pharmacovigilance Center; 7 subjects had symptoms, 4 had ALT elevations, 4 received NAC, but none had acute liver failure or died).

Brusilow SW, Cooper AJ. Encephalopathy in acute liver failure resulting from acetaminophen intoxication: new observations with potential therapy. *Crit Care Med* 2011; 39: 2550-3. PubMed PMID: 21705899.

(22 year old woman with an acetaminophen overdose [15 g] presented 36 hours later with nausea [biliurbin 12.9 mg/dL, ALT 6710 U/L, ammonia >200 microM], but went into coma at 72 hours as ammonia and ALT levels fell suggesting that brain glutamine rather than ammonia was responsible for coma).

King JP, Davis TC, Bailey SC, Jacobson KL, Hedlund LA, Di Francesco L, Parker RM, et al. Developing consumer-centered, nonprescription drug labeling a study in acetaminophen. *Am J Prev Med* 2011; 40: 593-8. PubMed PMID: 21565649.

(Interviews of 6 consumer focus groups found only 31% of participants knew that Tylenol contained acetaminophen and many had a poor understanding of "active ingredient"; authors recommended use of icons for portraying the active ingredient and maximum dose).

Mitchell SJ, Hilmer SN, Murnion BP, Matthews S. Hepatotoxicity of therapeutic short-course paracetamol in hospital inpatients: impact of ageing and frailty. *J Clin Pharm Ther* 2011; 36: 327-35. PubMed PMID: 21545612.

(Among 71 hospitalized patients treated with acetaminophen [3-4 g/day for at least 5 days], mean ALT levels at 5 days were higher in younger patients and in older patients who were not frail, but specific results not given).

Ferner RE, Dear JW, Bateman DN. Management of paracetamol poisoning. *BMJ* 2011; 342: 2218. PubMed PMID: 21508044.

(Review of management of acetaminophen overdose).

Heard KJ, Green JL, James LP, Judge BS, Zolot L, Rhyee S, Dart RC. Acetaminophen-cysteine adducts during therapeutic dosing and following overdose. *BMC Gastroenterol* 2011; 11: 20. PubMed PMID: 21401949.

(Most subjects participating in clinical trials of therapeutic doses of acetaminophen had detectable levels of cysteine adducts in serum, but always <1.1 nmol/mL, while subjects with severe hepatotoxicity [ALT >1000 U/L] usually had levels >1.1 nmol/mL).

Alhelail MA, Hoppe JA, Rhyee SH, Heard KJ. Clinical course of repeated supratherapeutic ingestion of acetaminophen. *Clin Toxicol (Phila)* 2011; 49: 108-12. PubMed PMID: 21370947.

(Among 503 acetaminophen overdose cases treated with N-acetylcysteine, 119 [24%] were considered due to repeated supratherapeutic ingestion of whom 41 [34%] developed ALT >1000 U/L, 4 died and 2 had a liver transplant; hepatotoxicity occurred only in those with raised ALT at presentation [lowest 252 U/L] and was more frequent in those with a history of alcoholism, viral hepatitis, and INR above 1.5 or creatinine 1.3 mg/dL at presentation).

Heard K. Asymptomatic alanine aminotransferase elevations with therapeutic doses of acetaminophen. *Clin Toxicol (Phila)* 2011; 49: 90-3. PubMed PMID: 21370944.

(Editorial on frequency and possible significance of ALT elevations occurring during acetaminophen therapy as identified in several prospective studies; virtually all cases were self limiting, asymptomatic and without accompanying bilirubin elevations).

Offerman SR. The clinical management of acetaminophen poisoning in a community hospital system: factors associated with hospital length of stay. *J Med Toxicol* 2011; 7: 4-11. PubMed PMID: 20857257.

(Retrospective analysis of 435 cases of acetaminophen overdose managed in the Northern California Kaiser Permanente system between 2003 and 2008 found similar hospital length of stay with iv as with oral N-acetylcysteine therapy; 4 patients died, none underwent liver transplantation).

Khandelwal N, James LP, Sanders C, Larson AM, Lee WM; and the Acute Liver Failure Study Group. Unrecognized acetaminophen toxicity as a cause of indeterminate acute liver failure. *Hepatology* 2011; 53: 567-76. (PubMed PMID: 21274877.

Among 110 patients with acute liver failure of unknown cause, 20 [18%] had acetaminophen-cysteine adducts above 1.0 nmol/mL, all of whom had other features suggestive of acetaminophen injury [young age, female sex, ALT > 1000 U/L, modest bilirubin elevations, high rate of spontaneous survival]).

Claridge LC. Detection of acetaminophen-cysteine adducts in cases of indeterminate liver failure is not diagnostic of intentional overdose. *Hepatology* 2011; 54: 746-7. PubMed PMID: 21360569.

(Letter in response to Khandelwal [2011] suggesting that all cases of indeterminate acute liver failure should be treated with N-acetylcysteine).

Bisschops LA, Bisschops WA, Vroegop MP, van Rossum LK, Kramers C. [Intentional paracetamol intoxication in children]. *Ned Tijdschr Geneesk* 2011; 155: A2132. Dutch. PubMed PMID: 21262016.

(Review of management of acetaminophen overdose in children).

Ceelle I, James LP, Gijsen V, Mathot RA, Ito S, Tesselaar CD, Tibboel D, Koren G, de Wildt SN. Acute liver failure after recommended doses of acetaminophen in patients with myopathies. *Crit Care Med* 2011; 39: 678-82. PubMed PMID: 21242792.

(Two girls, ages 12 and 17, with myopathies were treated with recommended doses of rectal acetaminophen and developed acute liver failure [AST >2000 U/L, acetaminophen-cysteine adducts >1 nmol/mL], given N-acetylcysteine, one died and one survived; suggested an increased susceptibility of patients with myopathy).

Craig DG, Bates CM, Davidson JS, Martin KG, Hayes PC, Simpson KJ. Overdose pattern and outcome in paracetamol-induced acute severe hepatotoxicity. *Br J Clin Pharmacol* 2011; 71: 273-82. PubMed PMID: 21219409.

(Among 938 patients with severe liver injury admitted to a Scottish Transplant center over an 18 year period, 663 were attributed to acetaminophen of which 75% were intentional, 17% unintentional, 8% unknown; the unintentional cases being older and having a lower spontaneous survival rate [57% vs 74%]).

Mehrpour O, Shadnia S, Sanaei-Zadeh H. Late extensive intravenous administration of N-acetylcysteine can reverse hepatic failure in acetaminophen overdose. *Hum Exp Toxicol* 2011; 30: 51-4. PubMed PMID: 20332167.

(18 year old man with acetaminophen overdose [34 g] presented with vomiting and jaundice 2 days later [ALT 870 U/L, bilirubin 10.3 mg/dL, INR 6], was given 6 days of iv N-acetylcysteine and survived).

Shah AD, Wood DM, Dargan PI. Understanding lactic acidosis in paracetamol (acetaminophen) poisoning. *Br J Clin Pharmacol* 2011; 71: 20-8. PubMed PMID: 21143497.

(Commentary on meaning of lactic acidosis in patients with acetaminophen overdose).

Beringer RM, Thompson JP, Parry S, Stoddart PA. Intravenous paracetamol overdose: two case reports and a change to national treatment guidelines. *Arch Dis Child* 2011; 96: 307-8. PubMed PMID: 21127004.

(Two infants, ages 5 and 6 months, were given a single incorrect dose of iv acetaminophen [75 and 90 rather than 15 mg/kg] and were given N-acetylcysteine, 1 developing liver injury [peak bilirubin 2.0 mg/dL, ALT 2819 U/L, INR 3.6], resolving within 6 days).

Klein-Schwartz W, Doyon S. Intravenous acetylcysteine for the treatment of acetaminophen overdose. *Expert Opin Pharmacother* 2011; 12: 119-30. PubMed PMID: 21126198.

(Review of the efficacy and safety of N-acetylcysteine for acetaminophen overdose suggests that standard regimen is adequate for uncomplicated cases with early presentation, but that extended courses may be better for high risk patients).

O'Connor ES, Schwarze ML, Kodner IJ, Keune JD. Surrogate decision making: a woman in fulminant liver failure after an acetaminophen overdose. *Surgery* 2011; 150: 1006-10. PubMed PMID: 22132422.

(Discussion of the ethical issues surrounding management of a woman with acute liver failure after acetaminophen overdose who is comatose and unable to provide consent for interventions including potentially life-saving liver transplantation).

Starkey Lewis PJ, Dear J, Platt V, Simpson KJ, Craig DG, Antoine DJ, French NS, et al. Circulating microRNAs as potential markers of human drug-induced liver injury. *Hepatology* 2011; 54: 1767-76. PubMed PMID: 22045675.

(Circulating miRNA-122 levels were elevated in patients with acute liver failure and particularly with acetaminophen overdose, with a higher dynamic range and more rapid recovery than ALT levels).

Zyoud SH, Awang R, Sulaiman SA. Reliability of the reported ingested dose of acetaminophen for predicting the risk of toxicity in acetaminophen overdose patients. *Pharmacoepidemiol Drug Saf* 2012; 21: 207-13. PubMed PMID: 21812068.

(Among 291 patients presenting within 24 hours of an acetaminophen overdose to a Malaysian hospital center, 97% of those reporting ingestion of >8 g had serum levels above the possible toxicity treatment line compared to only 3% of those reporting <8 g).

Dart RC, Rumack BH. Intravenous acetaminophen in the United States: iatrogenic dosing errors. *Pediatrics* 2012; 129: 349-53. PubMed PMID: 22271694.

(Review of the use and safety of iv acetaminophen [approved for use in the United States in 2011] and review of reports of 3 cases of dosing errors in children, only one of which was followed by liver injury and may not have been the cause).

Craig DG, Reid TW, Wright EC, Martin KG, Davidson JS, Hayes PC, Simpson KJ. The sequential organ failure assessment (SOFA) score is prognostically superior to the model for end-stage liver disease (MELD) and MELD variants following paracetamol (acetaminophen) overdose. *Aliment Pharmacol Ther* 2012; 35: 705-13. PubMed PMID: 22260637.

(Evaluation of two scoring systems [SOFA and MELD] for predicting acute liver failure and spontaneous survival in 138 patients with acetaminophen overdose).

Khawaja A, Shahab A, Hussain SA. Acetaminophen induced Steven Johnson syndrome-toxic epidermal necrolysis overlap. *J Pak Med Assoc* 2012; 62: 524-7. PubMed PMID: 22755330.

(40 year old woman took two doses of acetaminophen for fever and developed rash with oral and eye involvement evolving into severe SJS/TEN overlap [liver tests reported to be normal], ultimately recovery with corticosteroids, no rechallenge).

Zhou L, Maviglia SM, Mahoney LM, Chang F, Orav EJ, Plasek J, Boulware LJ, et al. Supratherapeutic dosing of acetaminophen among hospitalized patients. *Arch Intern Med* 2012; 172: 1721-8. PubMed PMID: 23401887.

(Analysis of electronic health records from 2 tertiary care hospitals over a 6 month period found 14,411 patients who were exposed to acetaminophen, the dose exceeding 4 g daily in 955 [7%]).

Rodriguez Lopez M, Perez Saborido B, Pacheco Sanchez D, Asensio Diaz E, Labarga Rodriguez F, Martinez Diaz R, Gonzalo Martin M, et al. Transplantation for acute liver failure: report of results in the region of Castilla y Leon (Spain) after 10 years of activity. *Transplant Proc* 2012; 44: 2625-6. PubMed PMID: 23146476.

(among 325 patients undergoing liver transplantation at a single center in Spain between 2001-2011, 14 [4.3%] were done for acute liver failure, but none for acetaminophen overdose).

Ji P, Wang Y, Li Z, Doddapaneni S, Hertz S, Furness S, Sahajwalla CG. Regulatory review of acetaminophen clinical pharmacology in young pediatric patients. *J Pharm Sci* 2012; 101: 4383-9. PubMed PMID: 23073837.

(Review of the pharmacokinetics of acetaminophen in children as it relates to recommended doses: 10-15 mg/kg for children of 6 months to 12 years of age).

Marzilawati AR, Ngau YY, Mahadeva S. Low rates of hepatotoxicity among Asian patients with paracetamol overdose: a review of 1024 cases. *BMC Pharmacol Toxicol* 2012; 13: 8. PubMed PMID: 23021009.

(Among 1024 patients presenting with acetaminophen overdose during a 5 year period to 2 large public hospitals in Malaysia, 124 [12%] had mild and 73 [7%] severe hepatotoxicity [ALT >1000 U/L], but none died).

Bebarta VS, Shiner DC, Varney SM. A case of moderate liver enzyme elevation after acute acetaminophen overdose despite undetectable acetaminophen level and normal initial liver enzymes. *Am J Ther* 2014;21:382-4. PubMed PMID: 23011168.

(22 year old man had normal serum enzyme and no detectable acetaminophen in serum 16 hours after a suicidal overdose of 7.5-12.5 g, yet ALT levels subsequently rose peaking at ~405 U/L 2 days later, then falling rapidly).

Varney SM, Buchanan JA, Kokko J, Heard K. Acetylcysteine for Acetaminophen Overdose in Patients Who Weigh >100 Kg. *Am J Ther* 2012 Sep 24. [Epub ahead of print] PubMed PMID: 23011167.

(Analysis of a prospective study of iv vs oral acetylcysteine therapy of acetaminophen overdose identified 37 patients who weighed more than 100 kg of whom 34 received a weight-based dose, although recommendations are for a maximum dose based on a maximum weight of 100 kg [iv] or 110 kg [oral]).

Kaufman DW, Kelly JP, Rohay JM, Malone MK, Weinstein RB, Shiffman S. Prevalence and correlates of exceeding the labeled maximum dose of acetaminophen among adults in a U.S.-based internet survey. *Pharmacoepidemiol Drug Saf* 2012; 21: 1280-8. PubMed PMID: 23001694.

(An internet survey of 5649 persons regarding their understanding of the risks of acetaminophen found that 3618 used acetaminophen and 163 [4.5%] took more than 4 g daily at least once weekly, usually for chronic pain).

Goyal RK, Rajan SS, Essien EJ, Sangsiry SS. Effectiveness of FDA's new over-the-counter acetaminophen warning label in improving consumer risk perception of liver damage. *J Clin Pharm Ther* 2012; 37: 681-5. PubMed PMID: 22958105.

(Survey of 205 persons who were visiting a pharmacy regarding risks of acetaminophen found that new warning labels increased their assessment of risk).

Kane A, Mitchell SJ, Carroll PR, Matthews S, Hilmer SN. Characteristics of older and younger patients with suspected paracetamol toxicity. *Australas J Ageing* 2012; 31: 190-3. *(Among 359 patients admitted to a large medical center in Sydney who had detectable serum acetaminophen levels, PubMed PMID: 22950592.*

50 were 20-30 years old [younger group] and 25 were 65 or above [older group], the older being more likely to have unintentional overdose [90% vs 29%] and abnormal ALT levels [42% vs 6%], but all recovered regardless of age).

Iorio ML, Cheerharan M, Kaufman SS, Reece-Stremtan S, Boyajian M. Acute liver failure following cleft palate repair: a case of therapeutic acetaminophen toxicity. *Cleft Palate Craniofac J* 2013; 50: 747-50. PubMed PMID: 22937760.

(8 month old boy underwent cleft palate repair and 3 days later was admitted with lethargy, seizures and acute hepatitis [bilirubin 3.1 mg/dL, ALT 12,885 U/L] which was attributed to acetaminophen [levels 83 mg/L] prescribed for post surgical pain).

Leung PS, Lam K, Kurth MJ, Coppel RL, Gershwin ME. Xenobiotics and autoimmunity: does acetaminophen cause primary biliary cirrhosis? *Trends Mol Med* 2012; 18: 577-82. PubMed PMID: 22920894.

(Hypothesis that high doses of acetaminophen might cause modifications of PDH that could induce autoantibody [AMA] formation and that drugs or environmental toxins may play a pathogenetic role in primary biliary cirrhosis).

Rumack B, Heard K, Green J, Albert D, Bucher-Bartelson B, Bodmer M, Sivilotti ML, Dart RC. Effect of therapeutic doses of acetaminophen (up to 4 g/day) on serum alanine aminotransferase levels in subjects consuming ethanol: systematic review and meta-analysis of randomized controlled trials. *Pharmacotherapy* 2012; 32: 784-91. PubMed PMID: 22851428.

(Systematic review of 6 controlled trials of acetaminophen in persons who drink alcohol indicated that serum ALT levels did not change between baseline and day 4 of acetaminophen therapy [4 g daily]).

Waring WS. Paracetamol (acetaminophen) overdose and acetylcysteine administration: should the United Kingdom adopt a single '150-line'? *Br J Clin Pharmacol* 2012; 74: 1066-7. PubMed PMID: 22835053.

(Letter discussing use of a single timed plasma concentration of acetaminophen [150 mg/L: ~1 mmol/L] to recommend acetylcysteine therapy after suspected acetaminophen overdose).

Kjartansdottir I, Bergmann OM, Arnadottir RS, Björnsson ES. Paracetamol intoxications: a retrospective population-based study in Iceland. *Scand J Gastroenterol* 2012; 47: 1344-52. PubMed PMID: 22827594.

(Analysis of diagnostic registry of the National University Hospital of Iceland between 2004-2009 found a decline in rate of acetaminophen overdoses and only 7 cases of severe hepatotoxicity [1 death], liver injury being more common with accidental overdose, older age and alcohol use).

Suk KT, Kim DJ, Kim CH, Park SH, Yoon JH, Kim YS, Baik GH, et al. A prospective nationwide study of drug-induced liver injury in Korea. *Am J Gastroenterol* 2012; 107: 1380-7. PubMed PMID: 22733303.

(Among 371 cases of drug induced liver injury seen at 17 University hospitals in Korea between 2005-2007, only 9 [2%] were attributed to acetaminophen, 6 of which were attributed to overdose).

Waring WS. Criteria for acetylcysteine treatment and clinical outcomes after paracetamol poisoning. *Expert Rev Clin Pharmacol* 2012; 5: 311-8. PubMed PMID: 22697593.

(Different cut-offs on the lines on the Prescott normogram are used as criteria to administer acetylcysteine after acetaminophen overdose; among 1191 patients with overdose, 16% had levels above 200, 24% above 150 and 39% above 100 mg/L; but acute liver injury occurred in 3.7% vs 2.3% vs 1.9% of patients).

Ogilvie JD, Rieder MJ, Lim R. Acetaminophen overdose in children. *CMAJ* 2012; 184: 1492-6. PubMed PMID: 22664763.

(22 day old boy was given the incorrect dose of liquid acetaminophen [800 instead of 40 mg] in preparation of circumcision and had a blood levels of 1243 umol/L, was treated with acetylcysteine, and did well without ALT elevation or symptoms of toxicity).

Wolf MS, King J, Jacobson K, Di Francesco L, Bailey SC, Mullen R, McCarthy D, Serper M, Davis TC, Parker RM. Risk of unintentional overdose with non-prescription acetaminophen products. *J Gen Intern Med* 2012; 27: 1587-93. PubMed PMID: 22638604.

- (Structured interviews with 500 patients in US internal medicine practices found that 24% would use acetaminophen in doses above 4 g daily depending in part of the over-the-counter product being considered).*
- McQuade DJ, Dargan PI, Keep J, Wood DM. Paracetamol toxicity: What would be the implications of a change in UK treatment guidelines? *Eur J Clin Pharmacol* 2012; 68: 1541-7. PubMed PMID: 22527349.
- (Cost effective analysis suggesting that use of a single timed plasma acetaminophen concentration [150 mg/L] rather than two levels [100 or 200 mg/L] and clinical assessment of risk was optimal in guiding use of acetylcysteine for acetaminophen overdose).*
- Craig DG, Zafar S, Reid TW, Martin KG, Davidson JS, Hayes PC, Simpson KJ. The sequential organ failure assessment (SOFA) score is an effective triage marker following staggered paracetamol (acetaminophen) overdose. *Aliment Pharmacol Ther* 2012; 35: 1408-15. PubMed PMID: 22524320.
- (Based upon analyses of 138 patients with acetaminophen overdose, SOFA was superior to MELD in predicting spontaneous survival at 72 and 96 hours after overdose).*
- Argentieri J, Morrone K, Pollack Y. Acetaminophen and Ibuprofen overdosage. *Pediatr Rev* 2012; 33: 188-9. PubMed PMID: 22474118.
- (Short review of metabolism, indications, and appropriate dosages of acetaminophen and ibuprofen in children and the clinical features and management of overdose of each).*
- Martinez RM, Nordt SP, Cantrell FL. Prescription acetaminophen ingestions associated with hepatic injury and death. *J Community Health* 2012; 37: 1249-52. PubMed PMID: 22466137.
- (Analysis of California Poison Control database [2001-2010] for cases of prescription acetaminophen overdose with hepatic injury identified 40 cases [2 deaths, 1 liver transplant], most commonly with combinations of 500 mg of acetaminophen with hydrocodone or oxycodone and often with addition of an over-the-counter acetaminophen product).*
- Heard K, Bui A, Mlynarchek SL, Green JL, Bond GR, Clark RF, Kozer E, et al. Toxicity From Repeated Doses of Acetaminophen in Children: Assessment of Causality and Dose in Reported Cases. *Am J Ther* 2014 21: 174-83. PubMed PMID: 22407198.
- (Systematic review of literature of cases of acetaminophen hepatotoxicity in children associated with repeated dosing indicated that injury was associated only dosing over above the recommended daily dose [<75 mg/kg]).*
- Thornton SL, Minns AB. Unintentional chronic acetaminophen poisoning during pregnancy resulting in liver transplantation. *J Med Toxicol* 2012; 8: 176-8. PubMed PMID: 22415886.
- (22 year old woman in 2nd trimester of pregnancy took acetaminophen in doses of ~6 g daily for 2 weeks and presented with acute liver failure [initial bilirubin 2.8 mg/dL, ALT 1436 U/L, INR 1.6], progressive to stage 4 encephalopathy and undergoing successful liver transplantation; however fetus developed progressive enlargement of brain ventricles and was lost at 17 days after transplant).*
- Heard K, Green J. Acetylcysteine therapy for acetaminophen poisoning. *Curr Pharm Biotechnol* 2012; 13: 1917-23. PubMed PMID: 22352734.
- (Review and history of major controversies surrounding development, use and recommendations on acetylcysteine therapy of acetaminophen overdose).*
- Voigt MD. Predicting death in patients with acetaminophen-induced acute liver failure: the King's College Hospital model is on the SOFA, not the mat. *Liver Transpl* 2012; 18: 384-6. PubMed PMID: 22253086.
- (Editorial on use of SOFA, King's College criteria or MELD for predicting death from acetaminophen induced acute liver failure).*

Bond GR, Ho M, Woodward RW. Trends in hepatic injury associated with unintentional overdose of paracetamol (Acetaminophen) in products with and without opioid: an analysis using the National Poison Data System of the American Association of Poison Control Centers, 2000-7. *Drug Saf* 2012; 35: 149-57. PubMed PMID: 22149359.

(Analysis of the US National Poison Data System [2000-2007] identified ~120,000 cases of overdose with acetaminophen-opioid combination, reports increasing 70% over the time period and 1614 [1.3%] having mild liver injury [ALT >100 U/L] and 1115 [1%] severe [ALT >1000 U/L], with 165 deaths and 9 liver transplants; at the same time, ~127,000 cases were identified with acetaminophen alone, reports increasing by 44% and mild liver injury occurring in 2091 [1.6%] and severe in 2583 [2%] with 267 deaths and 23 liver transplants; thus, poisonings have increased faster than overall use, particularly those associated with combination prescription products).

Hawton K, Bergen H, Simkin S, Dodd S, Pocock P, Bernal W, Gunnell D, et al. Long term effect of reduced pack sizes of paracetamol on poisoning deaths and liver transplant activity in England and Wales: interrupted time series analyses. *BMJ* 2013; 346: f403.

(In 1998, legislation in the UK placed restrictions on pack sizes of acetaminophen which was followed by a fall in deaths due to acetaminophen overdose [both suicidal and unintentional] by 43% and reduction in listings for transplant by 61%, but a minimal [not significant] decline in actual transplants for acetaminophen overdose).

Antoine DJ, Dear JW, Lewis PS, Platt V, Coyle J, Masson M, Thanacoody RH, et al. Mechanistic biomarkers provide early and sensitive detection of acetaminophen-induced acute liver injury at first presentation to hospital. *Hepatology* 2013; 58: 777-87. PubMed PMID: 23390034.

(Testing plasma from 129 patients presenting after an acute acetaminophen overdose [with levels that warranted acetylcysteine therapy] showed elevations in miR-122, HMGB1 and K18 well before rises in ALT, which were predictive of subsequent liver injury and thus early, prognostic markers).

Gulmez SE, Larrey D, Pageaux GP, Lignot S, Lassalle R, Jové J, Gatta A, et al. Transplantation for acute liver failure in patients exposed to NSAIDs or paracetamol (acetaminophen): the multinational case-population SALT study. *Drug Saf* 2013; 36: 135-44. PubMed PMID: 23325533.

(Case population study of adults listed for transplantation between 2005 and 2007 at 52 transplant centers in Europe; among 9479 patients, 600 were registered for acute liver failure, 192 of whom had been exposed to acetaminophen [111: 18.5% with overdose]).

James LP, Chiew A, Abdel-Rahman SM, Letzig L, Graudins A, Day P, Roberts D. Acetaminophen protein adduct formation following low-dose acetaminophen exposure: comparison of immediate-release vs extended-release formulations. *Eur J Clin Pharmacol* 2013; 69: 851-7. PubMed PMID: 23052410.

(Acetaminophen protein adducts were detected in serum within hours of ingestion of low dose acetaminophen [either immediate- or extended-release], but at levels [<0.1 nmol/mL] far below those associated with acetaminophen induced acute liver failure [>1 nmol/mL]).

Possamai LA, McPhail MJ, Quaglia A, Zingarelli V, Abeles RD, Tidswell R, Puthuchery Z, et al. Character and temporal evolution of apoptosis in acetaminophen-induced acute liver failure. *Crit Care Med* 2013; 41: 2543-50. PubMed PMID: 23949472.

(Patients with acute liver failure had high initial levels of total and caspase-cleaved cytokeratin-18 [biomarkers for apoptosis], which fell rapidly with recovery).

McGill MR, Jaeschke H. Apoptosis or necrosis in acetaminophen-induced acute liver failure? New insights from mechanistic biomarkers*. *Crit Care Med* 2013; 41: 2653-4. PubMed PMID: 24162681.

(Editorial in response to Possamai [2013]).

Hewett DG, Shields J, Waring WS. Missed paracetamol (acetaminophen) overdose due to confusion regarding drug names. *Curr Drug Saf* 2013; 8: 203-6. PubMed PMID: 23914754.

(Patient with an intentional overdose of acetaminophen referred to it as "Advil" for which reason acetylcysteine therapy was delayed).

De-Giorgio F, Lodise M, Chiarotti M, d'Aloja E, Carbone A, Valerio L. Possible Fatal Acetaminophen intoxication with atypical clinical presentation. *J Forensic Sci* 2013; 58: 1397-400. PubMed PMID: 23822653.

(63 year old woman developed hemorrhagic bullae, rhabdomyolysis, disseminated intravascular coagulation and acute renal failure [direct bilirubin 2.3 mg/dL, ALT 67 U/L, CPK 4462 U/K, creatinine 5.3 mg/dL], toxicology screening demonstrating elevated acetaminophen levels [78 mg/L] and autopsy showing steatosis, hepatitis and focal necrosis).

Rangnekar AS, Ellerbe C, Durkalski V, McGuire B, Lee WM, Fontana RJ. Quality of life is significantly impaired in long-term survivors of acute liver failure and particularly in acetaminophen-overdose patients. *Liver Transpl* 2013; 19: 991-1000. PubMed PMID: 23780824.

(Among 282 adults who survived acute liver failure spontaneously [157] or with liver transplantation [125], quality of life assessments 1-2 years later showed lower general health scores than population controls, with lowest values among spontaneous survivors of acetaminophen overdose).

Franko KR, Mekeel KL, Woelkers D, Khanna A, Hemming AW. Accidental acetaminophen overdose results in liver transplant during second trimester of pregnancy: a case report. *Transplant Proc* 2013; 45: 2063-5. PubMed PMID: 23769109.

(22 year old woman took high doses of APAP for dental pain during her 2nd trimester of pregnancy and presented with acute liver failure and underwent emergency liver transplantation; 17 days later the fetus was lost; same case as Thornton [2012]).

Zhou L, Maviglia SM, Rocha RA. The ability of a retrospective review of electronic health records to fully capture the frequency of supratherapeutic dosing of acetaminophen--reply. *JAMA Intern Med* 2013; 173: 1036. PubMed PMID: 23752971.

(Estimated rates of regular use of aspirin [19%] and NSAIDs [12%] in the general, US adult population in 2010 from the National Health Interview Survey, representing a 57% [aspirin] and 41% [NSAIDs] increase since 2005; use was higher in whites and with increasing age).

Leonis MA, Alonso EM, Im K, Belle SH, Squires RH; Pediatric Acute Liver Failure Study Group. Chronic acetaminophen exposure in pediatric acute liver failure. *Pediatrics* 2013; 131: e740-6. PubMed PMID: 23439908.

(Among 666 children with acute liver failure in a prospective database, 85 [13%] had a single dose exposure to acetaminophen and 83 [13%] chronic exposure; the two groups had similar clinical features [ALT 5140 vs 2384 U/L], but chronic exposure cases were younger [mean age 3.5 vs 15 years], less likely female [46% vs 82%], and more likely to die [12% vs 2%], however only 22% of them were diagnosed as acetaminophen overdose [37% were "indeterminant"]).

Green JL, Heard KJ, Reynolds KM, Albert D. Oral and intravenous acetylcysteine for treatment of acetaminophen toxicity: a systematic review and meta-analysis. *West J Emerg Med* 2013; 14: 218-26. PubMed PMID: 23687539.

(Metaanalysis of published literature on oral vs iv acetylcysteine for treatment and prevention of acetaminophen toxicity found similar rates of subsequent hepatitis [12.6% vs 13.2%], failures correlating best with delay in therapy, but no direct comparisons).

Court MH, Freytsis M, Wang X, Peter I, Guillemette C, Hazarika S, Duan SX, et al; Acute Liver Failure Study Group. The UDP-glucuronosyltransferase (UGT) 1A polymorphism c.2042C>G (rs8330) is associated with increased human liver acetaminophen glucuronidation, increased UGT1A exon 5a/5b splice variant mRNA ratio, and decreased risk of unintentional acetaminophen-induced acute liver failure. *J Pharmacol Exp Ther* 2013; 345: 297-307. PubMed PMID: 23408116.

(Among 260 patients with acute liver failure tested for UDP-glucuronosyltransferase [UGT] 1A polymorphism rs8330, a higher frequency of the c.2042C>G variant [enhanced glucuronidation] was found among those with unintentional [29%] than those with intentional acetaminophen overdose [46%] or other causes [42%] or matched population controls).

Kuehn BM. FDA: Acetaminophen may trigger serious skin problems. *JAMA* 2013; 310: 785. PubMed PMID: 23982356.

(Discussion of FDA warning that acetaminophen may cause Stevens Johnson Syndrome [SJS] or toxic epidermal necrolysis [TEM], a review identifying at least 91 cases, some with no other exposures and others with a positive rechallenge).

Manchanda A, Cameron C, Robinson G. Beware of paracetamol use in alcohol abusers: a potential cause of acute liver injury. *N Z Med J* 2013; 126: 80-4. PubMed PMID: 24157994.

(Commentary suggesting that the syndrome of acute serious liver injury from chronic therapeutic use of acetaminophen in alcoholic patients is underrecognized and not adequately assessed in prospective studies).

Bunchorntavakul C, Reddy KR. Acetaminophen-related hepatotoxicity. *Clin Liver Dis.* 2013; 17: 587-607, viii. PubMed PMID: 24099020.

(Comprehensive review of liver injury caused by acetaminophen with discussion of pathogenesis, epidemiology, risk factors, clinical manifestations, diagnosis, management and role of liver transplantation).

Lee WM. Drug-induced acute liver failure. *Clin Liver Dis* 2013; 17: 575-86, viii. PubMed PMID: 24099019.

(Overview of acute liver failure caused by medications which accounts for more than half of cases in recent prospective US registries; among 2000 cases in an adult registry, 916 [46%] were due to acetaminophen and 220 [10%] to other medications; N-acetylcysteine may be beneficial for both forms of acute injury).

James LP, Gill P, Simpson P. Predicting risk in patients with acetaminophen overdose. *Expert Rev Gastroenterol Hepatol* 2013; 7: 509-12. PubMed PMID: 23984999.

(Commentary on use of biomarkers to predict acetaminophen hepatotoxicity and recent study by Anoiné [2013], stressing the need for a very high negative predictive value for any test result to guide management [withholding acetylcysteine therapy]).

Duffull SB, Isbister GK. Predicting the requirement for N-acetylcysteine in paracetamol poisoning from reported dose. *Clin Toxicol (Phila)* 2013; 51: 772-6. PubMed PMID: 23964853.

(Among 1571 hospital admissions [1303 different patients] for acetaminophen overdose with a patient reported dose and known time of ingestion, acetaminophen levels were above the normogram line [150/1000] in 337 and 300 received acetylcysteine found the reported dose a strong predictor, particularly if above 50 g).

Sanaei-Zadeh H. Reliability of the reported ingested dose for predicting the requirement of N-acetylcysteine in paracetamol overdose patients. *Clin Toxicol (Phila)* 2013; 51: 1239. PubMed PMID: 24138504.

(Letter in response to Duffull [2013] pointing out other publications on the issue of reliability of patient reported dose of acetaminophen).

Thulin P, Nordahl G, Gry M, Yimer G, Aklillu E, Makonnen E, Aderaye G, et al. Keratin-18 and microRNA-122 complement alanine aminotransferase as novel safety biomarkers for drug-induced liver injury in two human cohorts. *Liver Int* 2013 Sep 11. [Epub ahead of print] PubMed PMID: 24118944.

(Analysis of serum samples from patients given maximum recommended dose of acetaminophen [Watkins 2006] found elevations in cytokeratin-18 markers [M65] and miR-122 arising before increases in ALT in serum and reaching higher relative values).

Civan JM, Navarro V, Herrine SK, Riggio JM, Adams P, Rossi S. Patterns of acetaminophen use exceeding 4 grams daily in a hospitalized population at a tertiary care center. *Gastroenterol Hepatol (N Y)* 2014; 10: 27-34. PubMed PMID: 24799836.

(Analysis of inpatient electronic medical records from a single tertiary care hospital from 2008 to 2010 for acetaminophen doses identified 43,761 patients given acetaminophen, only 2.6% of whom received more than 4 g per day, often caused by use of multiple acetaminophen containing products).

McGill MR, Cao M, Svetlov A, Sharpe MR, Williams CD, Curry SC, Farhood A, et al. Argininosuccinate synthetase as a plasma biomarker of liver injury after acetaminophen overdose in rodents and humans. *Biomarkers* 2014; 19: 222-30. PubMed PMID: 24597531.

(Argininosuccinate synthetase was found to increase early in the course of liver injury due to acetaminophen in rodents; testing of patients with liver injury from acetaminophen found high levels of ASS mirroring increases in ALT).

Mendizabal M, Marciano S, Videla MG, Anders M, Zerega A, Balderramo DC, Chan D, et al. Changing etiologies and outcomes of acute liver failure: perspectives from 6 transplant centers in Argentina. *Liver Transpl* 2014; 20: 483-9. PubMed PMID: 24425668.

(Retrospective analysis of cases of acute liver failure admitted to 6 liver transplant centers in Argentina between 2005 and 2011 identified 154 cases, 16 [10%] were attributed to drugs or toxins, but none to acetaminophen overdose).

Court MH, Peter I, Hazarika S, Vasiadi M, Greenblatt DJ, Lee WM; Acute Liver Failure Study Group. Candidate gene polymorphisms in patients with acetaminophen-induced acute liver failure. *Drug Metab Dispos* 2014; 42: 28-32. PubMed PMID: 24104197.

(Analysis of several candidate gene polymorphisms in patients with acute liver failure from intentional [n=78] or unintentional [n=79] acetaminophen overdose or other causes [n=103] found no statistically significant associations, although polymorphisms of CPY 3A5 and CD44 were somewhat overexpressed in acetaminophen cases).

Karczarek-Borowska B, Drzymala M, Golon K. [Hepatotoxicity of acetaminophen in a patient treated with capecitabine due to breast cancer]. *Pol Merkur Lekarsk* 2014; 36: 348-51. Polish. PubMed PMID: 24964515.

(Patient being treated with capecitabine for breast cancer developed liver dysfunction after taking acetaminophen [5.5 g daily for 3 days] for a viral infection).

Kang MH, Villablanca JG, Glade Bender JL, Matthay KK, Groshen S, Sposto R, Czarnecki S, et al. Probable fatal drug interaction between intravenous fenretinide, ceftriaxone, and acetaminophen: a case report from a New Approaches to Neuroblastoma (NANT) Phase I study. *BMC Res Notes* 2014; 7: 256. PubMed PMID: 24755475.

(7 year old boy with refractory neuroblastoma received experimental therapy with fenretinide and developed fever [day 4] followed by acute liver failure [peak bilirubin 22.8 mg/dL, ALT 1588 U/L, LDH 4231 U/L] with coagulopathy, ascites and lactic acidosis autopsy showing coagulative necrosis, attributed to interaction of acetaminophen, ceftriaxone and fenretinide).

Heard K, Rumack BH, Green JL, Bucher-Bartelson B, Heard S, Bronstein AC, Dart RC. A single-arm clinical trial of a 48-hour intravenous N-acetylcysteine protocol for treatment of acetaminophen poisoning. *Clin Toxicol (Phila)* 2014; 52: 512-8. PubMed PMID: 24708414.

(Among 309 patients with acetaminophen overdose presenting within 24 hours with potentially toxic serum levels who were treated with a 48 hour regimen of intravenous NAC, 18% developed ALT levels above 1000 U/L and one died).

Bucaretychi F, Fernandes CB, Branco MM, De Capitani EM, Hyslop S, Caldas JP, Moreno CA, Porta G. Acute liver failure in a term neonate after repeated paracetamol administration. *Rev Paul Pediatr* 2014; 32: 144-8. PubMed PMID: 24676202.

(26 year old male neonate was given acetaminophen orally for 3 days [10 mg/kg every 4 hours] by his breastfeeding mother who was also taking acetaminophen and presented with shock, jaundice and hepatomegaly [bilirubin 9.6 mg/dL, ALT 1087, INR 7.9, pH 7.21, glucose 18 mg/dL, ammonia 308 µg/dL], recovering with supportive measures and NAC with normal subsequent laboratory tests and neuropsychomotor development).

Michaut A, Moreau C, Robin MA, Fromenty B. Acetaminophen-induced liver injury in obesity and nonalcoholic fatty liver disease. *Liver Int* 2014; 34: e171-9. PubMed PMID: 24575957.

(Review of acetaminophen induced liver injury in obesity or nonalcoholic fatty liver disease mentions that results in animal models have been contradictory and there is no known association of increased susceptibility to liver injury from acetaminophen and body weight or fatty liver despite theoretical reasons why this might be so).

dela Cruz Ubaldo C, Hall NS, Le B. Postmarketing review of intravenous acetaminophen dosing based on Food and Drug Administration prescribing guidelines. *Pharmacotherapy* 2014; 34 Suppl 1: 34S-39S. PubMed PMID: 25521845.

(Retrospective analysis of 300 hospitalized patients who received intravenous acetaminophen for pain, found inappropriate dosing in 59 patients [20%], mostly due to not reducing dose for weight less than 50 Kg or continuing therapy for more than 24 hours; no serious adverse events were identified however).

Bateman DN, Dear JW, Carroll R, Pettie J, Yamamoto T, Elamin ME, Peart L, et al. Impact of reducing the threshold for acetylcysteine treatment in acute paracetamol poisoning: the recent United Kingdom experience. *Clin Toxicol (Phila)* 2014; 52: 868-72. PubMed PMID: 25200454.

(UK recommendations for acetaminophen levels qualifying for NAC therapy of overdose patients changed in 2012 from 150 [the US recommended levels] to 100 mg/dL and resulted in a marked increase in hospitalizations, use of NAC and medical costs with little evidence of improved outcomes).

Quartuccio L, Maset M, Soardo G, Avellini C, De Vita S. Acetaminophen-induced liver injury in a woman with febrile flare of systemic lupus erythematosus. *J Clin Rheumatol* 2014; 20: 349-51. PubMed PMID: 25160028.

(44 year old woman with systemic lupus developed rash and liver injury after being treated for fever with ciprofloxacin, amoxicillin/clavulanate and acetaminophen [4 g daily for 5 days] [bilirubin normal, ALT peak 1425 U/L, GGT 830 U/L, Alk P not given, INR normal], a liver biopsy suggesting acetaminophen injury and recovery with NAC and high dose prednisone).

Ward J, Kanchagar C, Veksler-Lublinsky I, Lee RC, McGill MR, Jaeschke H, Curry SC, Ambros VR. Circulating microRNA profiles in human patients with acetaminophen hepatotoxicity or ischemic hepatitis. *Proc Natl Acad Sci U S A* 2014; 111: 12169-74. PubMed PMID: 25092309.

(Testing serum and urine from 47 patients with acetaminophen overdose showed a positive correlation with number of microRNAs elevated in serum and ALT levels, usually rising before ALT elevations and demonstrating different patterns compared with ischemic liver injury).

Heard K, Green JL, Anderson V, Bucher-Bartelson B, Dart RC. A randomized, placebo-controlled trial to determine the course of aminotransferase elevation during prolonged acetaminophen administration. *BMC Pharmacol Toxicol* 2014; 15: 39. PubMed PMID: 25047090.

(Among 252 healthy outpatient volunteers treated with acetaminophen [4 g daily] or placebo for 16 days, ALT elevations occurred in 48 [23%] on acetaminophen vs 1[2%] on placebo and were above normal in 18 [9%] vs 1 [2%] and above twice normal in 6 [3%] vs none, with peak values at days 7-10 [highest 191 U/L]; continuation of acetaminophen to 40 days was followed by fall of values into the normal range in all except one patient).

Hedeland RL, Andersen J, Askbo N, Iskandar A, Jørgensen MH. Early predictors of severe acetaminophen-induced hepatotoxicity in a paediatric population referred to a tertiary paediatric department. *Acta Paediatr* 2014; 103: 1179-86. PubMed PMID: 25041517.

(Among 25 Danish children [22 girls, ages 11-16 years] with suicidal acetaminophen overdose and hepatotoxicity, acetaminophen intake ranged from 6.5 to 50 g and did not correlate with severity of injury; all recovered and only one had transient encephalopathy).

Curtis RM, Sivilotti ML. A descriptive analysis of aspartate and alanine aminotransferase rise and fall following acetaminophen overdose. *Clin Toxicol (Phila)* 2015; 53: 849-55. PubMed PMID: 26294195.

(Among 68 adults with acetaminophen overdose and hepatotoxicity, ALT and AST values rose and peaked together, but AST fell more rapidly than ALT [half-life of 15 vs 40 hours]).

Suzuki A, Yuen NA, Ilic K, Miller RT, Reese MJ, Brown HR, Ambroso JI, et al. Comedications alter drug-induced liver injury reporting frequency: Data mining in the WHO VigiBase™. *Regul Toxicol Pharmacol* 2015; 72: 481-90. PubMed PMID: 25988394.

(Analysis of a large database of cases of acetaminophen, isoniazid, valproate and amoxicillin/clavulanic acid induced liver injury found variation in frequency by specific comedications being taken).

Beger RD, Bhattacharyya S, Yang X, Gill PS, Schnackenberg LK, Sun J, James LP. Translational biomarkers of acetaminophen-induced acute liver injury. *Arch Toxicol* 2015; 89: 1497-522. PubMed PMID: 25983262.

(Review of results of studies of proteomics, transcriptomics and metabolomics to discover biomarkers to aid in diagnosis and management of acute acetaminophen hepatotoxicity focusing upon protein adducts for accurate diagnosis and microRNAs for prognosis and monitoring response to NAC and recovery).

Mengual-Moreno E, Lizarzabal-García M, Ruiz-Soler M, Silva-Suarez N, Andrade-Bellido R, Lucena-González M, Bessone F, et al. [Case reports of drug-induced liver injury in a reference hospital of Zulia state, Venezuela]. *Invest Clin* 2015; 56: 3-12. Spanish. PubMed PMID: 25920181.

(Among 13 patients presenting with drug induced liver injury at a Venezuelan hospital over a one year period, 2 were attributed to acetaminophen, both presenting a month after starting with mild-to-moderate serum aminotransferase elevations only, both resolving upon stopping).

Frey SM, Wiegand TJ, Green JL, Heard KJ, Wilkins DG, Gorodetsky RM, Dart RC. Confirming the causative role of acetaminophen in indeterminate acute liver failure using acetaminophen-cysteine adducts. *J Med Toxicol* 2015; 11: 218-22. PubMed PMID: 25896948.

(26 year old woman with recurrent severe acute hepatitis denied significant acetaminophen ingestion, but had typical clinical course and acetaminophen-cysteine adducts were detected in serum taken 4 days after presentation, securing the diagnosis and leading to her admitting to purposeful intake).

Alonso EM, James LP, Zhang S, Squires RH; Pediatric Acute Liver Failure Study Group. Acetaminophen Adducts Detected in Serum of Pediatric Patients With Acute Liver Failure. *J Pediatr Gastroenterol Nutr* 2015; 61: 102-7. PubMed PMID: 25859823.

(Among 393 children with acute liver failure, acetaminophen-cysteine adducts were detected in 50 of 58 [86%] with suspected acetaminophen overdose, 21 of 190 [11%] with indeterminate cause and 8 of 145 [5.5%] with specific causes).

- Harimoto N, Wang H, Ikegami T, Takeishi K, Itoh S, Yamashita YI, Yoshizumi T, et al. Education and imaging. Hepatology: Rare Stevens-Johnson syndrome and vanishing bile duct syndrome induced by acetaminophen, requiring liver transplantation. *J Gastroenterol Hepatol* 2015; 30: 656. PubMed PMID: 25776963.
- (40 year old woman developed Stevens Johnson syndrome attributed to acetaminophen [no information given on dose or timing or other exposures: bilirubin 27.9 mg/dL, ALT 17 U/L, Alk P 894 U/L, INR 1.3], undergoing living donor liver transplantation, explant showing vanishing bile duct syndrome).*
- Ioannides SJ, Siebers R, Perrin K, Weatherall M, Crane J, Travers J, Shirtcliffe P, Beasley R. The effect of 1g of acetaminophen twice daily for 12 weeks on alanine transaminase levels--A randomized placebo-controlled trial. *Clin Biochem* 2015; 48: 713-5. PubMed PMID: 25899926.
- (Among 94 adults with asthma treated with acetaminophen [2 g daily] or placebo for 12 weeks, ALT elevations above 3 times ULN arose in 1 subject in both groups, and mean ALT levels were minimally increased with acetaminophen [from 23.6 to 25.4 U/L], but not placebo [from 19.5 to 19.0 U/L]).*
- Hayward KL, Powell EE, Irvine KM, Martin JH. Can Paracetamol (Acetaminophen) be administered to Patients with Liver Impairment? *Br J Clin Pharmacol* 2015 Oct 13. [Epub ahead of print] PubMed PMID: 26460177.
- (Review of the safety of acetaminophen in patients with liver dysfunction mentions that serum levels are slightly higher in patients with cirrhosis and recommends more conservative dosing in patients with significant liver disease).*
- Graudins A. Paracetamol poisoning in adolescents in an Australian setting: not quite adults. *Emerg Med Australas* 2015; 27: 139-44. PubMed PMID: 25752743.
- (Among 187 adolescents presenting with acetaminophen overdose at 3 Australian medical centers during a 4 year period, 89% were girls, 53% ingested acetaminophen alone and 96% were intentional overdoses; 107 received NAC, none died or underwent liver transplantation; liver injury not mentioned).*
- Goldberg DS, Forde KA, Carbonari DM, Lewis JD, Leidl KB, Reddy KR, Haynes K, et al. Population-representative incidence of drug-induced acute liver failure based on an analysis of an integrated health care system. *Gastroenterology* 2015; 148: 1353-61. PubMed PMID: 25733099.
- (Among more than 4 million adults participating in an integrated health care system in Northern California, 62 developed possible or definite acute liver failure [ALF] of which 32 [52%] were due to drugs, including acetaminophen [18: 56%], HDS [6: 19%] and various prescription drugs [8:25%] including isoniazid [n=1] and amoxicillin/clavulanate [n=1]; 6 patients had liver transplant and 4 died; estimated incidence of ALF was 1.6 per million and acetaminophen ALF 1 per million population).*
- Yang X, Salminen WF, Shi Q, Greenhaw J, Gill PS, Bhattacharyya S, Beger RD, et al. Potential of extracellular microRNAs as biomarkers of acetaminophen toxicity in children. *Toxicol Appl Pharmacol* 2015; 284: 180-7. PubMed PMID: 25708609.
- (Comparison of microRNA profiling among 8 children with acetaminophen overdose and hepatotoxicity, to 10 children on therapeutic doses and 10 normal children demonstrated increases in 8 different microRNAs with hepatic injury including miRNA-122 and -375).*
- Kocaaslan ND, Tuncer FB, Tutar E, Celebiler O. Acute liver failure and hepatic encephalopathy after cleft palate repair. *Cleft Palate Craniofac J* 2015; 52: 629-31. PubMed PMID: 25689020.
- (12 month old boy underwent cleft palate repair and received rectal and oral acetaminophen of 96 mg/kg for one day and 60 mg/kg daily for 3 days and presented with bloody vomiting, severe hypoglycemia and liver failure [bilirubin 1.3 mg/dL, ALT 2467 U/L, INR 3.1], responding to supportive care).*
- Lee PJ, Shen M, Wang S, Spiegler P, Caraccio T, DeMuro JP, Malone B. Possible hepatotoxicity associated with intravenous acetaminophen in a 36-year-old female patient. *P T* 2015; 40: 123-32. PubMed PMID: 25673962.

(36 year old woman received 6 days of intravenous acetaminophen [~4 g daily] and developed marked liver injury [bilirubin 2.0 mg/dL, ALT 6600 U/L, AST 4833 U/L, Alk P normal, INR 3.8], ultimately recovering after stopping acetaminophen and administering NAC).

McGovern AJ, Vitkovitsky IV, Jones DL, Mullins ME. Can AST/ALT ratio indicate recovery after acute paracetamol poisoning? Clin Toxicol (Phila) 2015; 53: 164-7. PubMed PMID: 25652258.

(Among 37 patients with hepatotoxicity from acetaminophen overdose, the AST/ALT ratio of <0.5 was highly indicative of values after the peak of enzyme elevations in patients who recovered).

Holt EW, DeMartini S, Davern TJ. Acute liver failure due to acetaminophen poisoning in patients with prior weight loss surgery: a case series. J Clin Gastroenterol. 2015; 49: 790-3. PubMed PMID: 25551211.

(Among 101 patients with acute liver failure presenting at a single California transplant center over a 3 year period, 9 of 54 subjects with acetaminophen overdose vs none of 47 with ALF of other causes had a history of weight loss surgery; course and outcome of acetaminophen related ALF was similar between those with bariatric surgery and those without, two-thirds of cases were unintentional overdose).

Lancaster EM, Hiatt JR, Zarrinpar A. Acetaminophen hepatotoxicity: an updated review. Arch Toxicol 2015; 89: 193-9. PubMed PMID: 25537186.

(Review of acetaminophen hepatotoxicity focusing upon pathophysiology [CYP 2E1 metabolism], risk factors [decrease in glutathione or upregulation of CYP 450], clinical presentation, management [NAC, and use of Rumack-Matthew normogram], liver support systems, liver transplantation and outcomes).

Park HJ, Kim SR, Leem DW, Moon IJ, Koh BS, Park KH, Park JW, et al. Clinical features of and genetic predisposition to drug-induced Stevens-Johnson syndrome and toxic epidermal necrolysis in a single Korean tertiary institution patients-investigating the relation between the HLA -B*4403 allele and lamotrigine. Eur J Clin Pharmacol 2015; 71: 35-41. PubMed PMID: 25327504.

(Among 30 cases of SJS/TEN seen at a single Korean medical referral center between 2010 and 2014, 8 were attributed to lamotrigine, 8 to allopurinol, and 3 to acetaminophen).

Rajanayagam J, Bishop JR, Lewindon PJ, Evans HM. Paracetamol-associated acute liver failure in Australian and New Zealand children: high rate of medication errors. Arch Dis Child 2015; 100: 77-80. PubMed PMID: 25228327.

(Among 54 cases of acute liver failure in children seen at two pediatric transplant centers in Australia [Brisbane] and New Zealand [Auckland] between 2001 and 2012, 14 were due to acetaminophen overdose, 12 in children <5 years of age and usually due to dosing error, range of doses 62 to 250 mg daily for 2 to 24 days; 3 underwent liver transplant, 2 died).

Mishima-Iwai M, Takahashi K, Yokode M, Kimura Y, Sawai Y, Ueda Y, Chiba T. Late-onset acetaminophen-induced allergic hepatitis with progression to chronicity. Hepatol Res 2015; 45: 814-7. PubMed PMID: 25088083.

(35 year old Japanese woman developed acute liver injury first noted 14 days after a 2-day course of acetaminophen, cefcapene and loxoprofen which progressed to an acute icteric hepatitis 6 weeks later [peak bilirubin 8.2 mg/dL, ALT 659 U/L, prothrombin index 35%] with ascites and encephalopathy responding to corticosteroids, but ALT elevations persisting with positive lymphocyte stimulation test to acetaminophen only).

Fontana RJ, Ellerbe C, Durkalski VE, Rangnekar A, Reddy RK, Stravitz T, McGuire B, et al.; US Acute Liver Failure Study Group. Two-year outcomes in initial survivors with acute liver failure: results from a prospective, multicentre study. Liver Int 2015; 35: 370-80. PubMed PMID: 25039930.

(Among 306 patients with acute liver failure due to acetaminophen overdose who survived for 21 days, 2 year mortality was 10.5%, but most occurred within 3 months and mortality correlated with age and severity of the acute episode [ALT levels, coma grade]).

Vliegenthart AD, Shaffer JM, Clarke JI, Peeters LE, Caporali A, Bateman DN, Wood DM, et al. Comprehensive microRNA profiling in acetaminophen toxicity identifies novel circulating biomarkers for human liver and kidney injury. *Sci Rep* 2015; 5: 15501. PubMed PMID: 26489516.

(Analysis of plasma samples from 27 patients with and 27 without organ injury due to acetaminophen overdose for microRNA found greatest increases with miR-122, -885 and -151aa and miR-122 was better than ALT in predicting severe toxicity at early time points).

Kulkarni S, Perez C, Pichardo C, Castillo L, Gagnon M, Beck-Sague C, Gereige R, et al. Use of Pediatric Health Information System database to study the trends in the incidence, management, etiology, and outcomes due to pediatric acute liver failure in the United States from 2008 to 2013. *Pediatr Transplant* 2015; 19 (8): 888-95. PubMed PMID: 26388211.

(Analysis of admissions to 16 US pediatric liver transplant centers from 2008 to 2013 identified 583 patients, 53% indeterminant, 19% acetaminophen, 9% autoimmune, 2.7% metabolic and 6.5% viral hepatitis; mortality rate only 5% and 73% survived with their native liver).

Serper M, Wolf MS, Parikh NA, Tillman H, Lee WM, Ganger DR. Risk Factors, Clinical presentation, and outcomes in overdose With acetaminophen alone or with combination products: results from the acute liver failure study group. *J Clin Gastroenterol* 2016; 50: 85-91. PubMed PMID: 26166142.

(Among 666 adults with acetaminophen overdose and acute liver failure seen between 1998 and 2012, 30% were taking acetaminophen alone, 14% with an antihistamine and 57% in a combination product with opioids; 62% of cases were unintentional which were most frequent with opioid combinations but course and outcomes were similar, transplantation within 7 days in 7%, death in 17%).

Seifert SA, Kovnat D, Anderson VE, Green JL, Dart RC, Heard KJ. Acute hepatotoxicity associated with therapeutic doses of intravenous acetaminophen. *Clin Toxicol (Phila)* 2016 Jan 14:1-4. [Epub ahead of print] PubMed PMID: 26763284.

(92 year old woman received 6 days of intravenous acetaminophen [1 g every 6 hours] for postoperative pain] and developed nausea, vomiting and epigastric pain [bilirubin 1.8 mg/dL, ALT 3914 U/L, AST 4698 U/L, INR 1.7, ammonia 60 µg/dL, APAP-CyS adducts 4 µM], responding to course of NAC).